

Management of a Complex Skin Defect of the Hand Using a MacGregor Flap after Detonator Explosion: A Case Report

Youness Mokhchani^{1,3*}, Bouchaib Chafry^{2,3}, Driss Benchebba^{2,3}, A. S. Bouabid^{2,3}, Mustapha Boussouga^{2,3}

¹Department of Orthopedic Surgery and Traumatology, Mohammed VI Military Hospital –Dakhla-Morocco

²Department of Orthopedic Surgery and Traumatology, Mohammed V Military Teaching Hospital

³Faculty of Medicine and Pharmacy, Mohammed V University, Rabat, 10000, Morocco

*Corresponding Author: Youness Mokhchani

Department of Orthopedic Surgery and Traumatology, Mohammed VI Military Hospital –Dakhla-Morocco

Article History: | Received: 06.04.2026 | Accepted: 22.05.2026 | Published: 02.06.2026 |

Abstract: We present the case of a 33-year-old patient who sustained a detonator explosion injury to the left hand, initially resulting in amputation of the last two fingers (little and ring fingers) as well as a large, complex wound. Primary management consisted of surgical debridement and lavage, empiric antibiotic therapy, and local wound care. After guided healing, a 6 × 3 cm skin defect persisted. Reconstruction using a MacGregor flap was performed. The article details the steps of marking along the groin crease, flap elevation, transfer to the hand, pedicle immobilization, and the second-stage division procedure. The outcome was favorable, with good flap integration and satisfactory functional recovery. The discussion reviews the indications, technical variations, and alternatives to this flap.

Keywords: Macgregor Flap, Skin Defect, Hand, Blast Injury, Groin Flap.

Copyright © 2026 The Author(s): This is an open-access article distributed under the terms of the Creative Commons Attribution 4.0 International License (CC BY-NC 4.0) which permits unrestricted use, distribution, and reproduction in any medium for non-commercial use provided the original author and source are credited.

INTRODUCTION

Traumatic injuries from detonator explosions are rare but often severe, predominantly affecting the dominant hand in young males [1]. They involve a combination of blast injuries, thermal burns, debris projection, and blast effects, resulting in complex tissue loss [2]. Initial management consists of exhaustive surgical debridement, empiric antibiotic therapy, and repeated local wound care to prevent infection and promote healing [3]. Despite guided wound healing, a deep skin defect exposing noble structures (tendons, nerves, bone) frequently persists [4]. In this setting, regional or distant flaps are indicated, and the MacGregor inguinal flap constitutes a reliable option for covering defects on the dorsal or palmar surface of the hand [5]. This axial flap, vascularized by the superficial circumflex iliac artery, provides thin, pliable skin coverage with an acceptable donor site [6]. We report the case of a 33-year-old patient who underwent a MacGregor flap for a skin defect of the left hand following a detonator explosion [7].

CASE REPORT

The patient was a 33-year-old right-handed man, with no significant medical history, working as a weapons instructor. He was the victim of an accidental explosion of a detonator he was handling with his left (non-dominant) hand. Initial examination in the emergency department revealed traumatic amputation of the 4th and 5th fingers (ring and little fingers) at the level of the proximal phalanx, with extensive soft tissue loss in the hypothenar region and the 5th metacarpal space, a wound contaminated with metallic debris and powder, without major vascular injury (Figure 1). A clean surgical amputation of the remaining two fingers was performed at the metacarpophalangeal joint level (with resection of the metacarpal heads), followed by extensive debridement and copious lavage with saline and povidone-iodine. Empiric dual antibiotic therapy was initiated with amoxicillin-clavulanate (10 days) and gentamicin (5 days), followed by daily local wound care (packing, dressing changes). The initial course was marked by guided wound healing achieved in 4 weeks, but with persistence of a well-demarcated 6 × 3 cm skin

defect with healthy borders and slight bone exposure (Figure 2).

Given this skin defect not amenable to skin grafting (due to bone exposure and the sensitivity of the area), reconstruction with a MacGregor flap was decided. The procedure was performed under general anesthesia in two operative stages.

First Stage: Flap Harvesting and Transfer

The patient was placed in a supine position. The donor site was the left groin. Anatomical landmarks were: the anterior superior iliac spine (ASIS), the groin crease, the inguinal ligament, and the femoral artery pulse. The MacGregor flap design is an elliptical or rectangular flap, centered on the axis of the superficial circumflex iliac artery (a branch of the femoral artery). The cutaneous axis lies 2 cm below and parallel to the inguinal ligament, from the ASIS to a point 8-10 cm medially. Marking was performed with a dermatographic pen: a length of 7 cm and a width of 5 cm (slightly larger than the defect) were measured (Figure 3). The skin paddle was centered on the presumed course of the pedicle. Preoperative Doppler was used to verify the presence of the superficial pedicle. The incision began at the upper border, incising skin, subcutaneous tissue, and superficial fascia. The superficial circumflex iliac artery, running horizontally 1-2 cm below the inguinal ligament accompanied by two venae comitantes, was identified.

The flap was raised from lateral to medial, with careful dissection of the pedicles down to their origin from the femoral artery. Once the flap was fully vascularized, the pedicle was checked for twisting (Figures 4-5). The hand was then brought against the groin region, and the flap was sutured without tension to the edges of the defect using interrupted 2-0 nylon sutures (Figure 6). A suction drain was placed under the flap and at the donor site. The arm was immobilized with an elbow-to-hand plaster splint, maintained in adduction against the abdomen for 21 days.

Second Stage: Flap Division

At 21 days postoperatively, after clinical confirmation of good vascularization (pink coloration, satisfactory venous tourniquet test), a second procedure was performed under locoregional anesthesia. The pedicle was incised at its junction with the hand, the flap was freed, and the skin edges of the hand and groin were sutured. The donor site was closed primarily with an intradermal running suture.

The postoperative course was uneventful: 100% flap take, donor site healing in 10 days, no infection. Passive then active rehabilitation began at the 4th week. At 6 months follow-up, the flap was supple, well-integrated, with no significant contracture. The patient returned to his professional activities with technical adaptations.

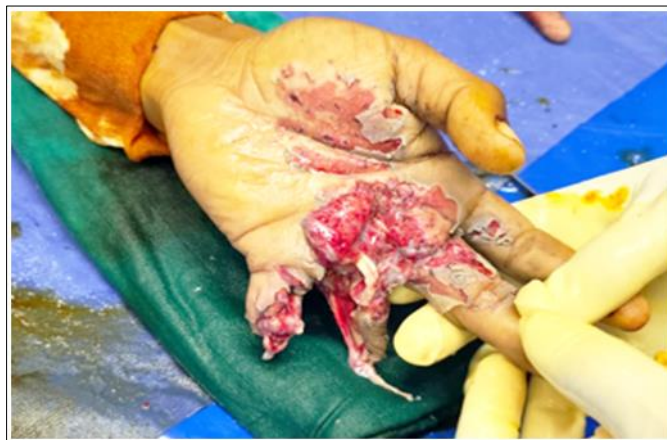

Figure 1: Appearance of the left hand after trauma

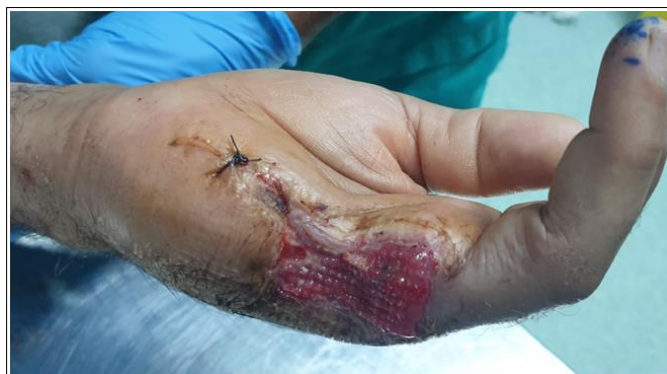

Figure 2: Appearance of the left hand after healing, showing the area of skin loss

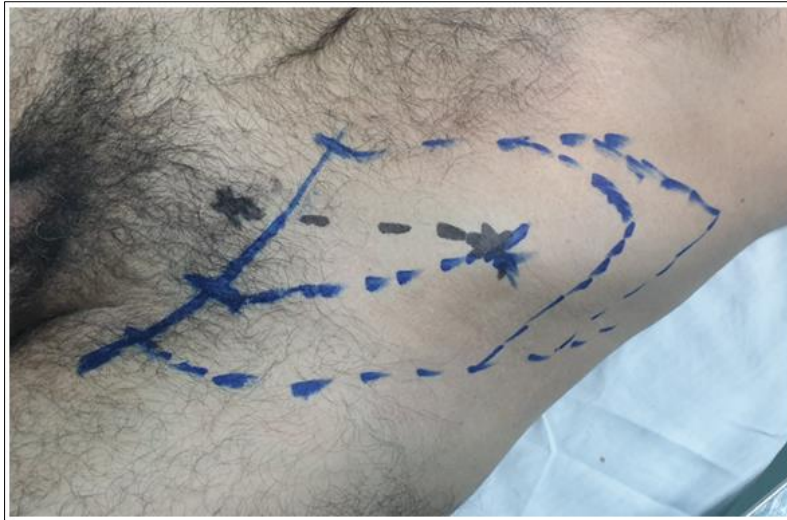


Figure 3: Pre-operative image showing the location of the flap harvest area

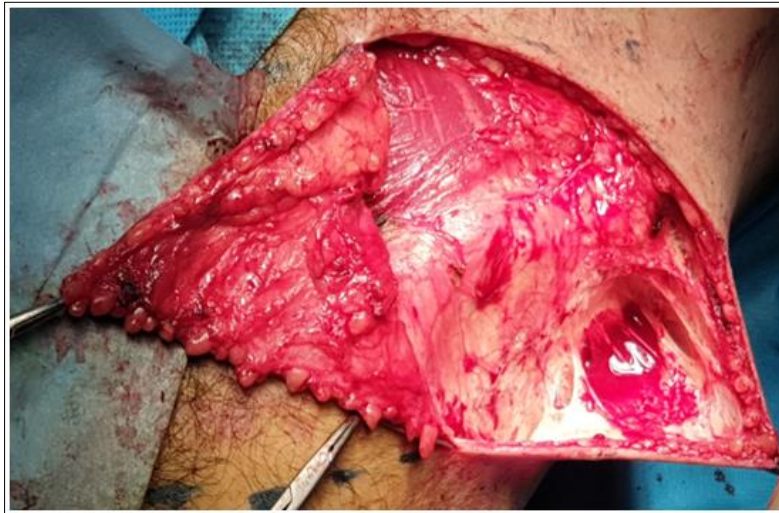


Figure 4: showing intraoperative image of dissection and isolation of the flap

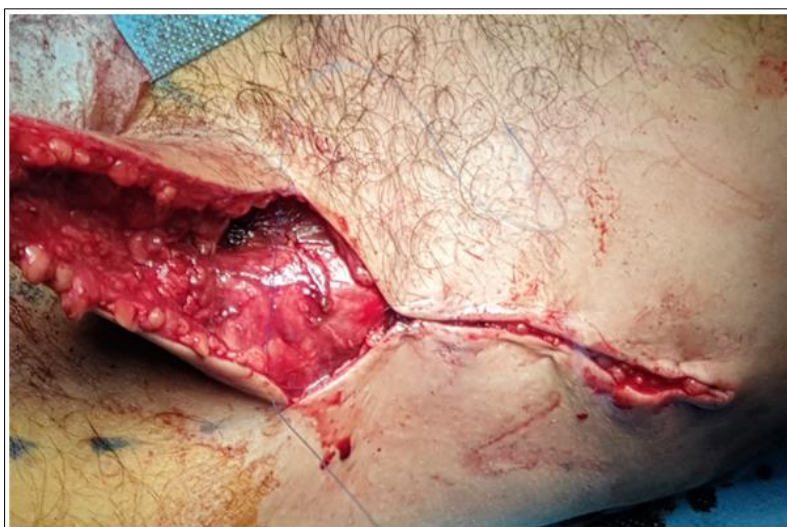

Figure 5: showing intraoperative image of closure of the flap donor area

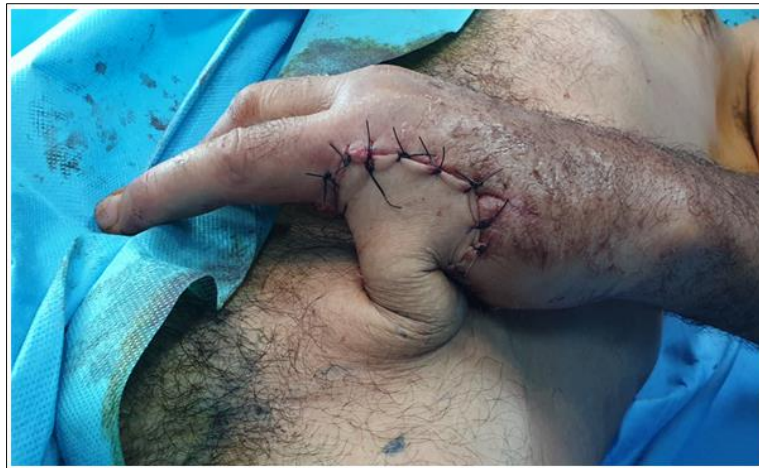

Figure 6: Showing postoperative image after flap transfer and suturing to the defect in the hand

DISCUSSION

The MacGregor flap is an axial groin flap based on the superficial circumflex iliac artery, whose reliability is well-established for hand skin defects (success rate >95% in published series) [1]. Unlike the cross-finger flap or thenar flap, it allows coverage of large areas (up to 10 × 6 cm) without requiring microsurgery [2]. In our case, the 6 × 3 cm defect exposed bone and tendons, making skin graft unsuitable as it would have caused adhesions, loss of mobility, and pain over the bone [3]. The critical step is marking: the flap must be placed strictly along the axis of the pedicle, identifiable by Doppler, 2 cm below the groin crease, to avoid distal necrosis [5]. Some authors recommend a minimum delay of 3 weeks before division, a delay we respected to allow peripheral neovascularization [6]. Possible complications include partial flap necrosis (about 5%), pedicle compression from a poorly positioned splint, and shoulder or elbow stiffness due to prolonged immobilization [7]. Modern alternatives such as the radial forearm flap (Chinese flap) offer better sensation but at the cost of arterial sacrifice and an unsightly forearm scar [8]. The MacGregor flap remains indicated for non-dominant hands in young, motivated patients, as adduction contracture can be prevented by early physiotherapy [9]. In our case, the functional result was satisfactory, providing skin coverage that protected tendons and bone, and preserved digital mobility [10].

CONCLUSION

The MacGregor flap is a reliable and reproducible surgical technique for reconstructing complex skin defects of the hand, particularly after blast injuries. Its success relies on rigorous adherence to anatomical landmarks (groin crease, iliac spine, pedicle

axis), appropriate immobilization for 21 days, and delayed division. Despite the emergence of microsurgical free flaps, this pedicled flap retains specific indications, particularly in the absence of microsurgical facilities or in cases of extensive lesions. Early rehabilitation after the second stage helps prevent stiffness and optimize functional recovery.

BIBLIOGRAPHY

1. McGregor IA, Jackson IT. The groin flap. *Br J Plast Surg.* 1972;25(1):3-5.
2. Smith PJ, Ross DA. The groin flap in hand reconstruction: a 20-year experience. *J Hand Surg Br.* 1999;24(2):178-183.
3. Duparc J, Mallet J. Les lambeaux pédiculés de l'aîne. *Ann Chir Plast.* 1980;25(3):217-222.
4. Lister GD, McGregor IA, Jackson IT. The groin flap in hand injuries. *Injury.* 1973;4(3):229-238.
5. Chwei-Chin C, Shyi-Gen C, Lai CS. The use of the groin flap for reconstruction of the hand. *Ann Plast Surg.* 1996;36(5):458-463.
6. Hou Z, Zhang Y. Timing of pedicle division in groin flap transfer. *J Reconstr Microsurg.* 2004;20(6):425-429.
7. Lebreton E, Guillier D. Complications du lambeau inguinal. *Rev Chir Orthop.* 2011;97(4):377-382.
8. Yang GF, Chen PJ, Gao YZ. The free radial forearm flap for hand reconstruction. *Plast Reconstr Surg.* 1981;68(1):25-31.
9. Gottlieb LJ, Krieger LM. Rehabilitation after groin flap immobilization. *Hand Clin.* 2002;18(4):667-674.
10. Saint-Cyr M, Wong C, Schaverien M. The groin flap: a reappraisal. *J Plast Reconstr Aesthet Surg.* 2009;62(10):1304-1310.