

Atypical Presentation of Bilateral Primary Testicular Lymphoma- A Diagnostic Dilemma

Dr. Parampreet Singh Sandhu¹, Dr. Amandeep Singh², Dr. Ashutosh Talwar^{3*}, Dr. Haramritpal Kaur⁴, Rajvir Kaur⁵, Anna Nibhoria⁶

¹Assistant Prof., Department of Surgery and Pathology, GGS Medical College, Faridkot, Punjab, India

²Prof., Department of Surgery and Pathology, GGS Medical College, Faridkot, Punjab, India

³Associate Prof., Department of Surgery and Pathology, GGS Medical College, Faridkot, Punjab, India

⁴Prof., Department of Surgery and Pathology, GGS Medical College, Faridkot, Punjab, India

⁵Assistant Prof., Department of Surgery and Pathology, GGS Medical College, Faridkot, Punjab, India

⁶Junior Resident, Department of Surgery and Pathology, GGS Medical College, Faridkot, Punjab, India

*Corresponding Author: Dr. Ashutosh Talwar

Associate Prof., Department of Surgery and Pathology, GGS Medical College, Faridkot, Punjab, India

Article History: | Received: 07.02.2026 | Accepted: 31.03.2026 | Published: 02.05.2026 |

Abstract: Primary testicular lymphoma (PTL) is a rare extranodal malignancy arising from the testis, accounting for approximately 5% of all testicular tumors and 1–2% of non-Hodgkin lymphomas, with diffuse large B-cell lymphoma being the predominant histological subtype. It is typically described as a disease of elderly males, whereas testicular tumors in younger individuals are more commonly non-seminomatous germ cell tumors, often associated with elevated tumor markers such as alpha-fetoprotein and beta-human chorionic gonadotropin. We report a case of a 40-year-old man who presented with painless, progressively enlarging bilateral testicular swelling over a period of 2–2.5 months. Clinical examination revealed enlarged, non-tender testes bilaterally. Ultrasonography demonstrated bilateral testicular enlargement with diffuse heterogeneous echotexture, particularly involving the right testis measuring 6 × 3.6 cm, suggestive of diffuse pathology. Notably, tumor markers were within normal limits, posing a diagnostic challenge. The patient underwent bilateral high inguinal orchiectomy, and histopathological evaluation confirmed non-Hodgkin lymphoma. PTL is an aggressive malignancy with limited data guiding its management due to its rarity; however, orchiectomy remains both diagnostic and therapeutic, and early initiation of systemic therapy is recommended. This case is noteworthy for its atypical presentation with bilateral synchronous involvement, occurrence in a relatively younger patient, and absence of tumor marker elevation, mimicking seminomatous pathology and contributing to diagnostic ambiguity.

Keywords: Primary testicular lymphoma, testicular tumor, Orchiectomy, Immunohistochemistry, Diagnostic Dilemma.

Copyright © 2026 The Author(s): This is an open-access article distributed under the terms of the Creative Commons Attribution 4.0 International License (CC BY-NC 4.0) which permits unrestricted use, distribution, and reproduction in any medium for non-commercial use provided the original author and source are credited.

INTRODUCTION

Primary testicular lymphoma is an uncommon malignancy arising from lymphoid tissue of the testis and constitutes only a small fraction of both testicular tumors and extranodal lymphomas. Among its histological subtypes, diffuse large B-cell lymphoma is reported most frequently [1]. In contrast, the majority of testicular neoplasms are of germ cell origin, accounting for nearly 95% of cases, and are typically seen in younger men [2]. These tumors are often associated with elevated serum tumor markers such as alpha-fetoprotein and beta-human

chorionic gonadotropin in a significant proportion of patients [3].

Clinically, primary testicular lymphoma is more often described in elderly individuals and usually presents as a painless testicular mass [4]. Because of this age predilection, testicular swellings in relatively younger patients are commonly presumed to be germ cell tumors. However, atypical presentations may occur and can create diagnostic confusion, particularly when clinical findings do not correlate with biochemical markers.

Citation: Parampreet Singh Sandhu, Amandeep Singh, Ashutosh Talwar, Haramritpal Kaur, Rajvir Kaur, Anna Nibhoria (2026). Atypical Presentation of Bilateral Primary Testicular Lymphoma- A Diagnostic Dilemma. *SAR J Surg*, 7(3), 42-45.

In such situations, imaging modalities like ultrasonography and magnetic resonance imaging may suggest a malignant process but are not always definitive in distinguishing lymphoma from germ cell tumors [5]. Therefore, histopathological examination with immunohistochemistry remains essential for accurate diagnosis. We report a case of a 40-year-old male presenting with bilateral testicular enlargement and normal tumor markers, where initial clinical suspicion favored a germ cell tumor, but subsequent evaluation confirmed primary testicular lymphoma, underscoring the importance of considering alternative diagnoses in atypical presentations.

CASE PRESENTATION

A 40yr old man presented with painless bilateral testicular swelling which was progressively increasing in size over a period of 2-2.5 months. The patient reported no history of fever, Trauma, weight loss, night sweat, burning micturition and no past history of tuberculosis in patient, and in family. No family history of any Malignancy reported. On examination, bilateral testes were enlarged and non-tender. Left testis measured 8×5

cm and right testis measured 6×4cm with hard consistency. Overlying skin and spermatic cord were normal. Bilateral inguinal area was normal. No abdominal organomegaly noted, and no lymph node masses were palpable in the abdomen, inguinal area and supraclavicular areas.

Ultra-sonography whole abdomen with bilateral inguinoscrotal region revealed enlarged bilateral testes with diffuse heterogeneous echotexture of right testis measure (L×AP) =6×3.6cm suggestive of diffuse involvement and discrete space occupying lesions in left testis largest measure (L×Ap) =3×2.8 cm, left sided mild hydrocele with echoes. B/L spermatic cords were normal. It was suggestive of neoplastic etiology with differential diagnosis of epididymo-orchitis, tuberculosis. Further MRI was planned.

MRI Pelvis was suggestive of heterogeneous to hypotense T2W lesion involving b/L testes with moderate diffusion restriction and few of the lesion showing internal haemorrhage. Left hemorrhagic hydrocele was seen suggestive of malignant etiology as shown in Fig. 1.

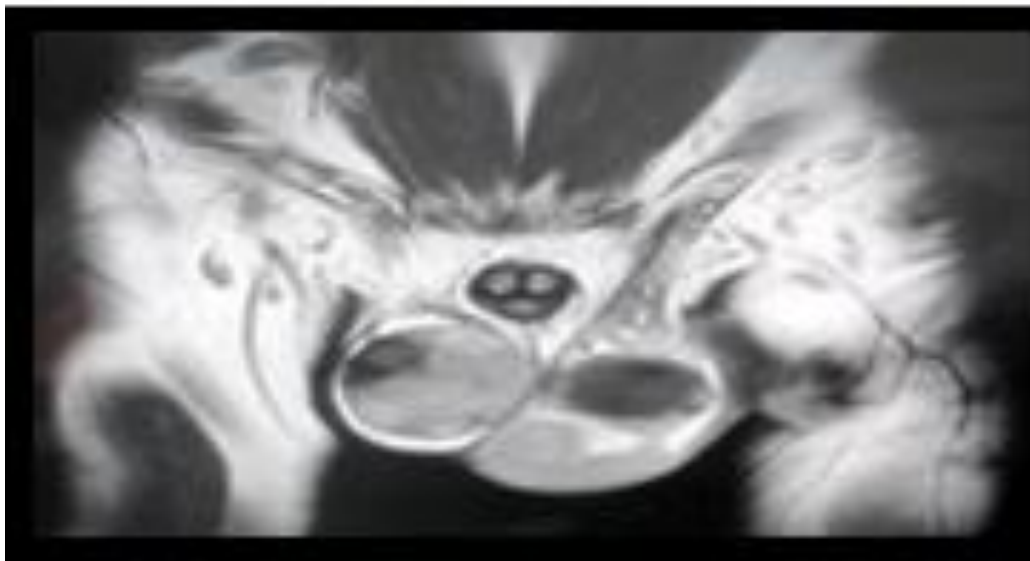


Fig. 1: MRI Pelvis showing heterogeneous to hypotense T2W lesion involving b/L testes with moderate diffusion restriction and few of the lesion showing internal haemorrhage

Serum tumor markers were done including Alpha Fetoprotien (4.14 ng/ml), Beta HCG (1.20mlu/ml) and LDH (178U/L) which were all within normal physiological limits.

Patient was taken up for bilateral high inguinal orcheidectomy and biopsy was sent for HPE. Histopathological examination was suggestive of non-Hodgkin's lymphoma (FIG.2) and Bilateral spermatic cords were free of tumor.

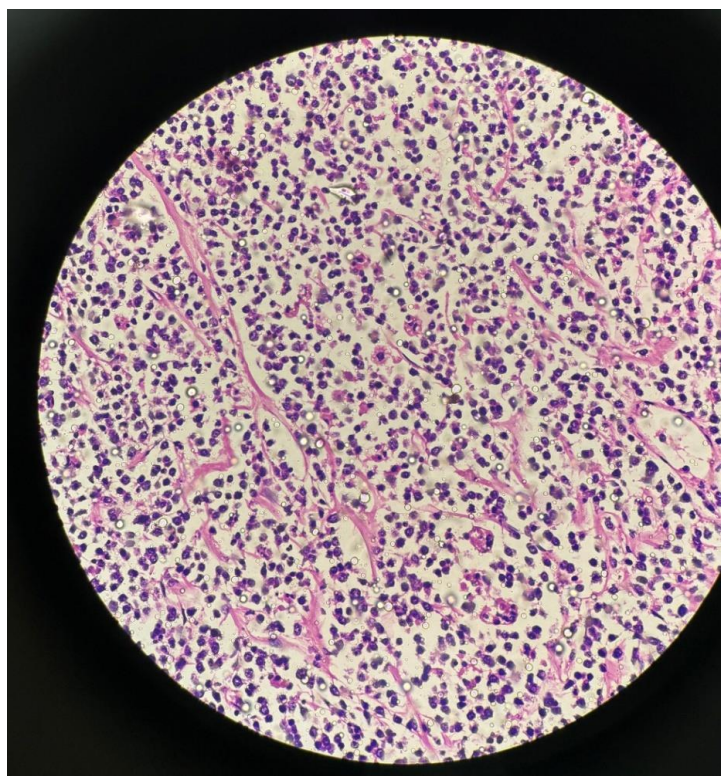


Fig. 2: Histology slide showing features of NHL

Immunohistochemistry showed Tumor Cells to be Positive for CD20, BCL2, BCL6(WEAK), MUM1, c-myc and negative for CD3, CD10, SOX11, TdT, CD23. Patient identity has been protected and he gave written informed consent for the publication of this case and any accompanying images. The patient was followed up in Radiotherapy department for further management post orchiectomy.

DISCUSSION

Primary testicular lymphoma is an uncommon extranodal malignancy, and its rarity limits the availability of large-scale epidemiological data. Among the different histological subtypes, diffuse large B-cell lymphoma is the most frequently encountered variant. Clinically, it often presents as a painless enlargement of the testis, which may either be localized or represent the initial manifestation of a more disseminated lymphoproliferative disorder.

Testicular lymphoma can be the first presentation of a clinically occult or primary extranodal disease. It is considered as one of the differential diagnoses of testicular masses, especially for patients older than 60 years [6]. A recent study by Wang *et al*; included 16 patients with primary testicular-DLBCL. The median age of the patients was 62 years [7]. Contrary to this our patient was a younger patient of 40 years age.

In the present case, the diagnostic dilemma arose due to the patient's age and bilateral testicular involvement, both of which initially suggested a germ cell tumor. However, the persistently normal tumor

markers were a key differentiating feature. In a typical 40-year-old patient with non-seminomatous germ cell tumor, AFP and/or β -hCG are elevated in the majority of cases, and their absence should prompt consideration of alternative diagnoses. This discordance between clinical suspicion and biochemical findings raised suspicion for a non-germ cell etiology, such as lymphoma.

Testicular lymphoma has a characteristic pattern of dissemination with involvement of contralateral testis, bones, lung, CNS and adjacent structure.

Ultrasonography and magnetic resonance imaging are commonly used imaging modalities in clinical practice. Ultrasonography findings may suggest focal or diffuse areas of hypoechogenicity with hypervascularity in an enlarged testis, and MRI allows the evaluation of both the testes, paratesticular spaces, and spermatic cord [8].

Primary testicular lymphoma treatment has been standardized. According to Wang *et al.*, systematic therapy should be considered in the early stages of PTL. Orchiectomy is mandatory and indicated as both diagnostic and therapeutic procedure. This may be followed by chemotherapy in advance stages.

Based on Ultrasonography and magnetic resonance imaging findings, in this case, High Inguinal Bilateral Orchiectomy was done and patient was discharged under stable condition to follow up with biopsy report.

Biopsy report was suggestive of bilateral NHL with Immunohistochemistry showing Tumor Cells to be Positive for CD20, BCL2, BCL6(WEAK), MUM1, c-myc and negative for CD3, CD10, SOX11, TdT, CD23.

Imaging modalities, including ultrasonography and MRI, supported a malignant process but lacked specificity to distinguish between lymphoma and germ cell tumors. Ultimately, histopathological examination with immunohistochemistry confirmed the diagnosis of diffuse large B-cell lymphoma. Bilateral involvement with younger age of presentation was thought to be seminomatous, but to our surprise turned out to be Bilateral NHL. Negative tumor markers however favoured the diagnosis of NHL. So, this whole scenario turned out to be a Diagnostic Dilemma.

CONCLUSION

Primary testicular lymphoma is a rare but important differential diagnosis for testicular masses, even in younger patients. This case highlights that bilateral testicular enlargement with normal tumor markers can pose a significant diagnostic dilemma, often mimicking germ cell tumors. Imaging may suggest malignancy but is not definitive; hence, histopathological examination with immunohistochemistry remains essential for diagnosis. Our case proved out to be bilateral primary testicular NHLs with atypical presentation in younger age group (favouring more towards seminoma) and rare bilateral synchronous lesion with negative tumor marker serology.

REFERENCES

1. Chen B, Cao DH, Lai L, Guo JB, Chen ZY, Huang Y, et al. Adult primary testicular lymphoma: clinical

features and survival in a series of patients treated at a high-volume institution in China. *BMC Cancer*. 2020;20(1):220. doi: 10.1186/s12885-020-6711-0. [DOI] [PMC free article] [PubMed] [Google Scholar]

2. Mazloom A, Fowler N, Medeiros LJ, Iyengar P, Horace P, Dabaja BS. Outcome of patients with diffuse large B-cell lymphoma of the testis by era of treatment: the M. D. Anderson Cancer Center experience. *Leuk Lymphoma* 2010 Jul;51(7):1217–24.
3. Thomas LC, Adonizio C, Filicko J, Golshayan AR, Costa LJ, Morris GJ. Testicular lymphoma. *SeminOncol* 2010;37:549–54.
4. Sahu KK, Mishra AK, Lal A, Oshea J. Testicular lymphoma: A rare cause of a testicular mass. *J Coll Physicians Surg Pak* 2020;30(5):556. [DOI] [PubMed] [Google Scholar]
5. Xu H, Yao F. Primary testicular lymphoma: A SEER analysis of 1,169 cases. *Oncol Lett* 2019;17(3):3113–24. [DOI] [PMC free article] [PubMed] [Google Scholar]
6. Chen WJ, Kuo JY, Lin CC, Chung HJ, Huang W, et al. Primary testicular lymphoma—A single center experience and review of literature. *Urol Sci* 2016;27(2):96–100. [Google Scholar]
7. Qi Wang, Dafang Zheng, Damin Chai, Shiwu Wu, Xiaolin Wang, Shaonan Chen, et al. Primary testicular diffuse large B-cell lymphoma: Case series. *Medicine (Baltimore)* 2020. Mar;99(12):e19463. [DOI] [PMC free article] [PubMed] [Google Scholar]
8. Cheah CY, Wirth A, Seymour JF. Primary testicular lymphoma. *Blood* 2014;123(4):486–93. [DOI] [PubMed] [Google Scholar]