

Rare Case of Malignant Gastrocolic Fistula

Samir Shukla¹, Sanjay Sisodia², Sanjay Vishwakarma², Raghavendra Shetty^{3*}, Umang Dudeja³

¹Professor, Dept. of General Surgery GMC Bhopal

²Associate Professor, Dept. of General Surgery GMC Bhopal

³Resident of General Surgery

*Corresponding Author: Raghavendra Shetty
Resident of General Surgery

Article History: | Received: 01.05.2025 | Accepted: 05.06.2025 | Published: 28.06.2025 |

Abstract: Malignant gastrocolic fistula is a rare and challenging clinical entity characterized by nonspecific symptoms, often leading to delayed diagnosis and management. Imaging modalities such as barium studies, contrast-enhanced CT scans, and upper gastrointestinal endoscopy are crucial for diagnosis. We report the case of a 44-year-old man who presented with anorexia, significant weight loss, and nausea. Upper GI endoscopy and colonoscopy revealed a gastrocolic fistula secondary to invasive adenocarcinoma involving the stomach extending into splenic flexure as a fistula. The patient underwent a D2 gastrectomy with Roux-en-Y gastrojejunostomy and left radical hemicolectomy. Histopathology confirmed moderately differentiated adenocarcinoma with lymph node involvement. This case highlights the importance of timely diagnosis and aggressive surgical management in improving outcomes in such rare malignancies.

Keywords: Gastrocolic Fistula, Adenocarcinoma of Stomach, Roux-en-Y Gastrojejunostomy, Left Radical Hemicolectomy.

Copyright © 2025 The Author(s): This is an open-access article distributed under the terms of the Creative Commons Attribution 4.0 International License (CC BY-NC 4.0) which permits unrestricted use, distribution, and reproduction in any medium for non-commercial use provided the original author and source are credited.

INTRODUCTION

Gastrocolic fistula is a rare pathological condition characterized by an abnormal communication between the stomach and the colon, most commonly involving the greater curvature of the stomach and the transverse colon. While such fistulae can result from benign conditions like peptic ulcer disease or pancreatitis, malignant causes-particularly advanced gastric or colonic adenocarcinoma-are less common and typically present at a late stage of disease progression.

In Western countries, adenocarcinoma of the transverse colon is the more frequently reported malignant cause of gastrocolic fistula, with an incidence of approximately 0.3-0.4% in operated cases. Clinical presentation is often non-specific, but the classical triad includes weight loss, feculent vomiting, and diarrhea. Due to the rarity and ambiguous symptomatology, diagnosis is often delayed, necessitating a high index of suspicion. Imaging techniques such as barium studies, contrast-enhanced CT scans, and endoscopic evaluation are crucial for detection and characterization.

This report presents a rare case of a malignant gastrocolic fistula secondary to synchronous gastric and colonic adenocarcinoma in a young male patient, managed successfully with en-bloc surgical resection.

CASE REPORT

A 44-year-old male presented with complaints of abdominal pain, anorexia, and unintentional weight loss of approximately 10 kg over a six-week period. On physical examination, he appeared emaciated and pale. Abdominal examination was unremarkable. Laboratory investigations revealed microcytic hypochromic anemia (hemoglobin: 6.8 g/dL), hypoproteinemia, and hypoalbuminemia (serum albumin: 2.1 g/dL).

Upper gastrointestinal endoscopy revealed a large gastrocolic fistula at the greater curvature of the stomach, with thickened proliferative mucosa. A biopsy from the site confirmed invasive adenocarcinoma (Grade I).

Citation: Samir Shukla, Sanjay Sisodia, Sanjay Vishwakarma, Raghavendra Shetty, Umang Dudeja (2025). Rare Case of Malignant Gastrocolic Fistula. *SAR J Surg*, 6(3), 62-65.

Colonoscopy demonstrated an ulceroproliferative obstructive lesion at the splenic flexure of the colon. Biopsy from this lesion revealed invasive adenocarcinoma (Grade II).

Contrast-enhanced computed tomography (CECT) of the abdomen revealed a short segment of irregular, heterogeneously enhancing. Asymmetric bowel wall thickening at the splenic flexure measuring 20.3 mm in thickness over a 5 cm segment. The lesion was seen infiltrating the greater curvature of the stomach and forming a fistulous tract measuring approximately 12 x 11 mm. There was smooth mural thickening and mucosal hyperenhancement along both the greater and lesser curvatures of the stomach.

The patient was initially stabilized with intravenous fluids and total parenteral nutrition (TPN) to address malnutrition. Subsequently, he underwent

surgical intervention involving a D2 gastrectomy with Roux-en-Y gastrojejunostomy and left radical hemicolectomy, Intraoperative findings included.

1. A 6x4 cm mass on the body of the stomach communicating with the transverse colon via a fistulous tract (Figure 1).
2. A 5x6 cm mass at the splenic flexure of the transverse colon with direct involvement of the stomach. (Figure 2).

Postoperative recovery was uneventful. The patient was discharged on postoperative day 12, Histopathological examination revealed moderately differentiated adenocarcinoma of the stomach (Figure 3) with lymph node involvement, and all resection margins were clear. The patient was referred to the oncology department for adjuvant chemotherapy. At follow-up, he remained alive and disease-free.

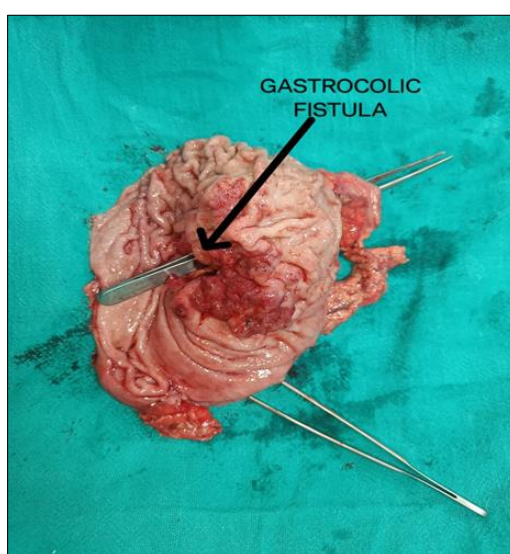

Figure 1: Mass of size 6 x 4 cm over body of stomach with ulcer communicating to transverse colon at splenic flexure through fistulous tract

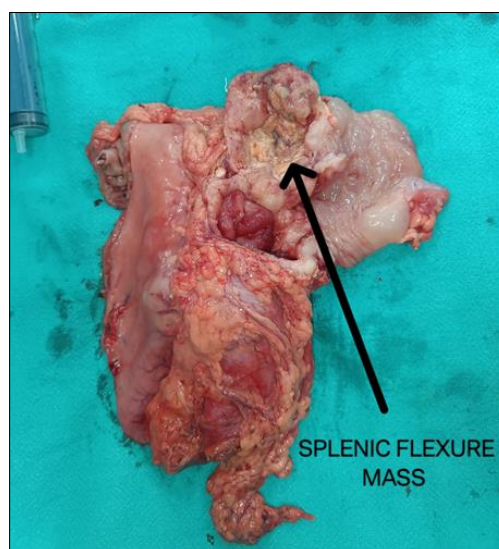


Figure 2: Mass of size 5 x 6 cm at splenic flexure of transverse colon communicating through fistulous tract

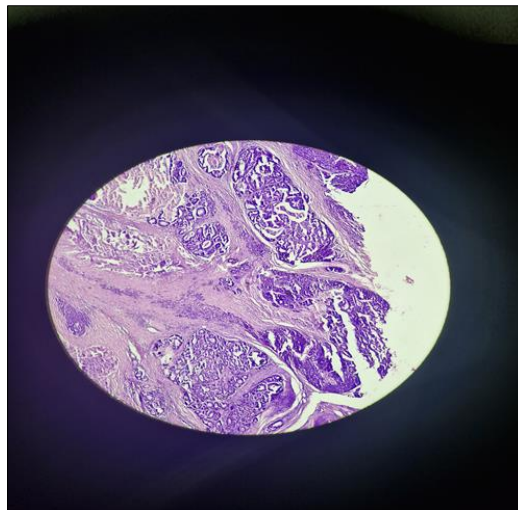


Figure 3: Histopathology of Adenocarcinoma of Stomach

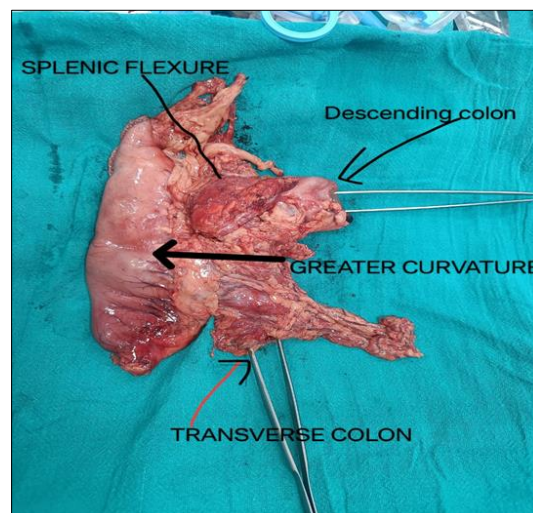


Figure 4: Entire specimen of resected mass

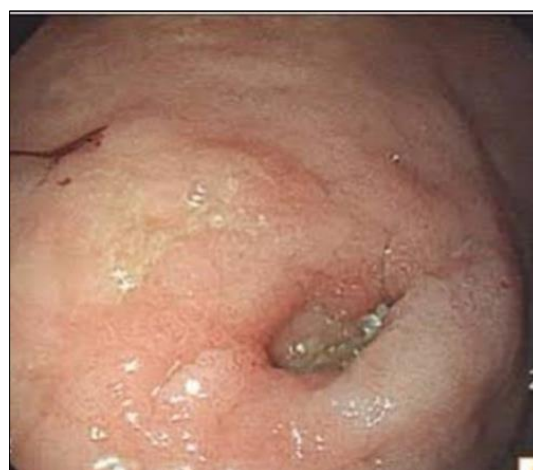

Figure 5: Endoscopic view of fistula from stomach

DISCUSSION

Gastrocolic fistula rare pathological communication between the epithelialized mucosal surfaces of the stomach and the colon. Its precise incidence is unknown. The first reported case was

described by Albrecht von Haller (11) in 1755, although it was not published in English literature. The first English-language case documented by Douglas Firth (12) in 1920, who attributed the fistula to a benign gastric ulcer [9].

Gastrocolic fistulas may result from benign or malignant conditions in recent decades, the widespread use of nonsteroidal anti-inflammatory drugs (NSAIDs) and aspirin has contributed to an increase in benign gastric ulcer-related fistula formation [2, 3]. However, in adults, the most common cause remains malignant disease of the stomach or colon, typically arising in advanced stages due to delayed diagnosis [4-10].

Two mechanisms are proposed for fistula formation:

- 1) Direct tumor invasion across gastro-colic omentum and
- 2) Inflammation-induced adherence and fistulation between the stomach and colon [3, 4]. Malignant gastro-colic fistulas are often characterized by large, Infiltrative tumors with surrounding inflammatory reaction [3, 4]

Clinically, patients may present with trait of weight loss, diarrhea, and feculent vomiting. The presence of feculent vomiting-caused by reflux of colonic content into the stomach is highly suggestive but occurs in only about 30% of cases [13]. Such fistulas often lead to severe anemia and nutritional deficiencies due to chronic gastrointestinal losses and malabsorption.

Diagnostic modalities include barium studies, upper gastrointestinal endoscopy, colonoscopy, and contrast-enhanced CT scans. CT is especially useful for defining the extent of disease and fistula formation [1]. Endoscopy offers direct visualization and tissue biopsy aiding in accurate diagnosis and confirmation of malignancy [4].

Gastrocolic fistulas are classified into three categories; Internal; between the stomach and colon (gastro-gastric or colo-gastric depending on primary site), External; between the colon and the skin (colo-cutaneous), Complex; involving a third organ such as pancreas or jejunum (Ex- gastro-jejuno-colic or gastro-pancreato-colic fistula) [10].

En bloc surgical resection is the preferred treatment and offers the best chance of long-term survival in malignant cases. Despite the advanced nature of disease, radical resection can be curative in selected patients [5-11]. Adjuvant chemotherapy is considered when lymph node involvement or incomplete resection is identified.

In our case, the patient underwent successful en-bloc resection with D2 gastrectomy and left hemicolectomy. Postoperative recovery was uneventful, and the patient remains disease-free at follow-up. This case highlights the importance of early recognition and aggressive surgical management in achieving favorable outcomes, even in rare and complex presentations such as malignant gastro-colic fistula.

Samir Shukla: Conceptualization, supervision, Validation

Sanjay Sisodiya: Investigation

Sanjay Vishwakarma: visualization

Raghavendra T: Data curation, Methodology, Writing, Software

Umang Dudeja: Resources

Funding: This work did not receive any grant from funding agencies in the public, commercial or not for profit sectors.

Conflict of Interest: There are no conflicts of interest to declare by any of the authors of this study.

REFERENCES

1. Lim CH, et al. Successful palliation of a gastrocolic fistula secondary to gastric cancer by insertion of a covered colonic stent. *Gastrointest Endosc.* 2011;73(6):1314-1317.
2. Marshall SF, Knud-Hansen J. Gastrojejunocolic and gastrocolic fistulas. *Ann Surg.* 1957;145(5):770-782.
3. Matsuo S, et al. Gastrocolic fistula originating from transverse colon cancer: report of a case and review of the Japanese literature. *Surg Today.* 1994;24(12):1085-1089.
4. Mallaiah L, et al. Malignant gastrocolic fistula: case report and review of the literature. *Am J Proctol Gastroenterol Colon Rectal Surg.* 1980;31(11):354-357.
5. Amlicke JA, Ponka JL. Gastrocolic and gastrojejunocolic fistulas. A report of sixteen cases. *Am J Surg.* 1964;107:744-750.
6. Christiansen S, et al. Management of gastrocolic fistula. *Am Surg.* 1981;47:63-66.
7. Firth D. A case of gastrocolic fistula. *The Lancet.* 1920;195(5046):1061.
8. Abeygunasekera S, et al. Gastropancreaticocolic fistula: complication of a benign ulcer. *Gastrointest Endosc.* 2004;59(3):450-452.
9. Forshaw MJ, Dastur JK. Long-term survival from gastrocolic fistula secondary to adenocarcinoma of transverse colon. *World J Surg Oncol.* 2005;3(1):9.
10. Cody J H, et al. Gastrocolic and gastro-jejuno-colic fistula: report of twelve cases and review of the literature. *Ann Surg.* 1975;181:376-380.
11. Haller A. *Opuscula pathologica, 1755. Voorheev N (Ed.), Die klinische und radiologische diagnose der fistula gastrocolica. Deutsch Arch Klein Med.* 1912;106:294-308. doi: 10.1515/9783111426709-010. [DOI] [Google Scholar] Stamatakis M, Karaiskos I, Pateras I,
12. Alexiou I, Stefanaki C, Kontzoglou K. Gastrocolic fistulae; From Haller till nowadays. *Int J Surg.* 2012;10(3):129-133. doi: 10.1016/j.ijsu.2012.02.011. [DOI] [PubMed] [Google Scholar]