

Case Report

Mucoepidermoid Carcinoma of the Palate: A Case Report and Literature Review

Dr. Dani Bouchra^{1*}, Dr. Olaya Hamid¹, Dr. Alain Francois Habimana¹, Pr. Boulaadas Malik¹

¹Maxillofacial Surgery and Stomatology Department, IBN SINA University Hospital, Rabat, Morocco

***Corresponding Author:** Bouchra Dani

Maxillofacial Surgery and Stomatology Department, IBN SINA University Hospital, Rabat, Morocco

Article History

Received: 11.04.2022

Accepted: 18.05.2022

Published: 24.05.2022

Abstract: Mucoepidermoid carcinoma (MEC) is the epithelial salivary gland neoplasm of the oral cavity. The most common pathological type for the salivary gland tumors of the head and neck was mucoepidermoid carcinoma. In our work, we report a case of mucoepidermoid carcinoma observed in a 50-year-old man. Clinically, he presented the ulcer-budding tumor of the soft palate, movable relative to the deep plan measuring 2,5 cm. The diagnosis was based on clinical, radiological and pathological arguments. Complete surgical excision is the treatment of choice in combination with postoperative radiotherapy and chemotherapy.

Keywords: Mucoepidermoid carcinoma, Palate, Case report.

INTRODUCTION

Mucoepidermoid carcinoma (MEC) is the most common malignant salivary gland neoplasm in the oral cavity [1], occurring mainly in the major salivary glands. The most common pathological type for the salivary gland tumors of the head and neck was mucoepidermoid carcinoma accounting for 40% followed by adenoid cystic carcinoma 31% [2].

About 5% of these tumors occur in patients younger than 18-year-old with women mostly affected [1, 2]. MEC of the palate presents as solitary painless lesion. Radical surgical excision is the cornerstone treatment. The management of this tumor is guided by its classification into high-grade and low-grade [4]. Prognosis of MECs is a function of the histological grade, clinical staging and adequacy of excision.

In our work we present a case of a tumor in a 50-year-old man and we discuss the clinical aspects and the diagnostic and therapeutic features.

OBSERVATION

We report the case of a 50-year-old man, having a history of Crohn's disease, who presented a tumor of the palate, progressively evolving during the 1 months in a context of a good general status. The clinical exam found a eupneic patient, in a good general condition, presenting the ulcer-budding tumor of the soft palate with an inflammatory bead around. The extra oral examination was unremarkable. No other abnormality was found. Intraoral examination found a painful mass, movable relative to the deep plan measuring 2,5 cm on its longest diameter, 1 cm from the uvula. Examination salivary glands and cervical lymph nodes is normal.

The CT scan of the facial bones noted the presence of a palate pathological process, centered on the soft palate, well limited with regular contours heterogeneous, discreetly enhanced after injection of the contrast product (fig.1).

The patient was admitted to the operating room. The treatment consisted of wide surgical excision of the lesion with free surgical margins which was carried out under general anesthesia with an electrocautery the patient did not

Copyright © 2021 The Author(s): This is an open-access article distributed under the terms of the Creative Commons Attribution 4.0 International License (CC BY-NC 4.0) which permits unrestricted use, distribution, and reproduction in any medium for non-commercial use provided the original author and source are credited.

Citation: Dani Bouchra, Olaya Hamid, Alain Francois Habimana, Boulaadas Malik (2022). Mucoepidermoid Carcinoma of the Palate: A Case Report and Literature Review. *South Asian Res J Oral Dent Sci*, 4(2), 7-9.

present any postoperative complications and the clinical and radiological follow-up after 9 months was satisfactory. Histologic analysis study of the resected specimen revealed mucosal and squamous cells. The tumoral architecture is made of solid masses and wide spans, confirming the diagnosis of the mucoepidermoid carcinoma high grade.

DISCUSSION

Mucoepidermoid carcinoma (MEC) is the epithelial salivary gland neoplasm of the oral cavity, accounting for 30% of all salivary malignancies [5]. and have been reported rarely. it can be located on retro molar area, buccal mucosa floor of the mouth, lips, and tongue [6].

Clinically, MEC mimic mucoceles or vascular lesions. Some patients suffering from pain, ulceration and hemorrhage. However, pain and indurated mass are indicators of a high grade MEC. Symptoms can also include paresthesia, dysphagia [7].

The classification used to describe the tumor is that of AFIP, it allows to define the low grade of intermediate or high grade. Diagnosis criteria are cystic component, nerve invasion, necrosis, mitosis and anaplasia. Histologically, the high-grade tumor characterized by mucosecretante cells and high mitotic activity. MEC expresses CK7, CK8, CK13, CK14, CK18, and CK19 with a varied positivity depending on the type and topography of the cells in the neoplastic growth patterns [8]. The differential diagnosis involves benign tumors like pleomorphic adenoma, mucocele, hemangioma and malignant tumors such as acinar cell carcinoma and myoepithelial carcinoma [6, 8].

The treatment of high-grade tumors is usually radical excision in combination with postoperative radiotherapy. Lymph node dissection is indicated for high grade T2_T4 and T4b tumors [2]. If there is bone erosion, removal of the involving bone is indicated [9].

Sometimes extended maxillectomy is necessary, the authors suggest an iliac crest free flap or scapular free flap for reconstruction of the palate, maxilla [10]. Bony reconstruction of palatal defects can allow dental implants to improve oral rehabilitation after surgery [11].

The prognosis factors are clinical stage, histological stage, surgical margins, perineural and vascular involvement and lymph node metastasis.

CONCLUSION

MEC is malignant tumors involving salivary glands are rare and account for less than 3% of head and neck cancers. MEC must be considered in differential diagnosis of intraoral swellings particularly for those located in the palate. The treatment of choice is radical excision and dissection neck with postoperative radiotherapy.

List of figures

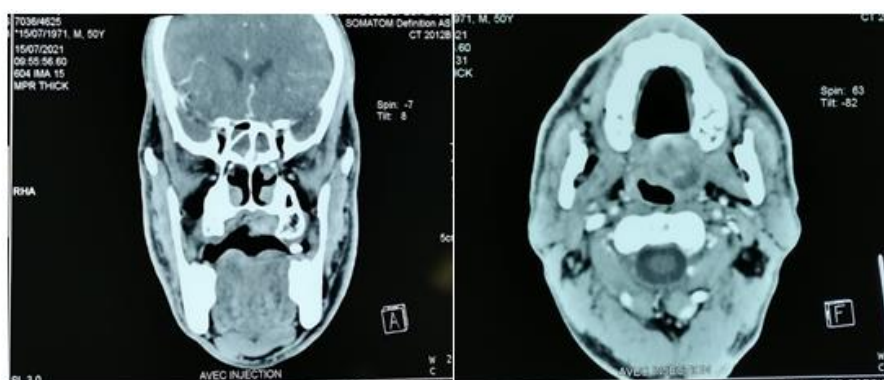


Fig-1: Coronal and axial CT scan showing a tumoral process of the soft palate, well limited with regular contours heterogeneous

Conflicts of interest

The authors declare no competing interest.

Authors' contributions

All the authors participated in the treatment of this patient and in the redaction of this article.

Declaration of patient consent

The authors certify that they have obtained all appropriate patient consent forms. In the form, the patient(s) has/have given his/her/their consent for his/her/their images and other clinical information to be reported in the journal. The patients understand that their names and initials will not be published and due efforts will be made to conceal their identity, but anonymity cannot be guaranteed.

REFERENCES

1. Fernando matheus santana tunel. (2020). John lennon silva cunha, anna monielly santos da silva, camila neiva porto silva, juliana batista melo da fonte, caetano guilherme carvalho pontes, and, ric. mucoepidermoid carcinoma of the hard palate: report of a case. September.
2. Bin Zhou1 Zhuo-shan Huang1Wei-liang ChenZi-xian Huang Rui Chen Kai-fang Yuan Lei Hong Yon-ju Chen. (2021). Outcomes of patients with minor salivary gland mucoepidermoid carcinoma of the palate undergoing submental flap reconstruction following radical resection. *Asian journal of surgery*.
3. Hicks, J., & Flaitz, C. (2000). Mucoepidermoid carcinoma of salivary glands in children and adolescents: assessment of proliferation markers. *Oral Oncology*, 36(5), 454-460.
4. Triantafillidou, K., Dimitrakopoulos, J., Iordanidis, F., & Koufogiannis, D. (2006). Mucoepidermoid carcinoma of minor salivary glands: a clinical study of 16 cases and review of the literature. *Oral diseases*, 12(4), 364-370.
5. Xu, W., Wang, Y., Qi, X., Xie, J., Wei, Z., Yin, X., ... & Han, W. (2017). Prognostic factors of palatal mucoepidermoid carcinoma: a retrospective analysis based on a double-center study. *Scientific reports*, 7(1), 1-11.
6. Jarde, S. J., Das, S., Narayanswamy, S. A., Chatterjee, A., & Babu, C. (2016). Mucoepidermoid carcinoma of the palate: A rare case report. *Journal of Indian Society of Periodontology*, 20(2), 203.
7. Bridonneau, T., Quinque, É., Zink, S., Schultz, P., Bornert, F., Onea, A., ... & Bahi-Gross, S. (2017). Le carcinome muco-épidermoïde du palais: présentation de deux cas et revue de la littérature. *Médecine Buccale Chirurgie Buccale*, 23(1), 37-44.
8. Ismail, A., Nachite, F., Labani, Y., Raji, A., Belbachir, A., Rais, H. (2018). Palatal Mucoepidermoid Carcinoma: A Rare Intraoral Malignancy. *Annals of medical and clinical oncology*. January.
9. Mathew, A. L., Joseph, B. B., Sarojini, D. M., Premkumar, P., & Sukumaran Nair, S. (2017). Mucoepidermoid Carcinoma of Palate—A Rare Entity. *Clinics and Practice*, 7(4), 145-147.
10. Aurora, V., Jason, Burkes, D.D.S., Fayette, Williams, DDS, MD, FACS., & Yadranko Ducic, FRCS(C), FACS. (2019). Free Flap Reconstruction of the Maxilla, 33(1); 30-37.
11. Cordeiro, P.G., Chen, C.M. (2012). A 15-year review of midface reconstruction after total and subtotal maxillectomy: part II. Technical modifications to maximize aesthetic and functional outcomes. *Plast Reconstr Surg*, 129(01);139-147.