

Review Article

Recent Advances in the Field of Reconstruction in Oral & Maxillofacial Surgery

Dr. Sandeep Kumar Sharma^{1*}, Dr. Dushyant Singh², Nidhi Sharma³, Shweta Verma⁴, Dr. Neha Srivastava², Dr. Diksha Bhatiya⁵, Dr. Pratishtha Agarwal⁵, Dr. Deepika Chandel⁵, Dr Devna Sharma⁵, Dr. Ngurang Anam⁵

¹Resident, Department of Oral & Maxillofacial Surgery, K.D Dental College & Hospital, NH 2, Near Chatti Kara, Mathura, Kota, Uttar Pradesh 281121, India

²Senior Lecturer, K.D Dental College & Hospital, NH 2, Near Chatti Kara, Mathura, Kota, Uttar Pradesh 281121, India

³Undergraduate Student, ITS Dental College Muradnagar Ghaziabad, NH 34, Ghaziabad, Uttar Pradesh 201206, India

⁴Undergraduate Students, K.D Dental College & Hospital, NH 2, Near Chatti Kara, Mathura, Kota, Uttar Pradesh 281121, India

⁵P.G Student, K.D Dental College & Hospital, NH 2, Near Chatti Kara, Mathura, Kota, Uttar Pradesh 281121, India

*Corresponding Author

Dr. Sandeep Kumar Sharma

Article History

Received: 08.10.2021

Accepted: 12.11.2021

Published: 16.11.2021

Abstract: Reconstruction within the head and neck is challenging. Defects can be anatomically complex and may already be compromised by scarring, inflammation, and infection. Tissue grafts and vascularised flaps (either pedicled or free) bring healthy tissue to a compromised wound for optimal healing and are the current gold standard for the repair of such defects, but disadvantages are their limited availability, the difficulty of shaping the flap to fit the defect and, most importantly, donor site morbidity. The importance of function and aesthetics has driven advances in the accuracy of surgical techniques. We discuss current advances in reconstruction within oral and maxillofacial surgery. Developments in navigation, three-dimensional imaging, stereolithographic models, and the use of custom-made implants can aid and improve the accuracy of existing reconstructive methods. Robotic surgery, which does not modify existing techniques of reconstruction, allows access, resection of tumours, and reconstruction with conventional free flap techniques in the oropharynx without the need for mandibulotomy. Tissue engineering and distraction osteogenesis avoid the need for autologous tissue transfer and can therefore be seen as more conservative methods of reconstruction. Recently, facial allotransplantation has allowed whole anatomical facial units to be replaced with the possibility of sensory recovery and reanimation being completed in a single procedure. However, patients who have facial allotransplants are subject to life-long immunosuppression so this method of reconstruction should be limited to selected cases [1].

Keywords: Tissue grafts, Robotic surgery, tumours, Tissue engineering.

INTRODUCTION

The specialty of Oral & Maxillofacial Surgery (OMFS), as we know it now, will inevitably change in our lives. The use of new scientific and technological achievements has revolutionized field of oral and maxillofacial surgery. OMS is, in itself, an integral field that encompasses aspects of science, clinical techniques and esthetics and constantly re-creates itself.

Over the past two decades, the field of Oral and Maxillofacial Surgery (OMS) has grown significantly, and every breakthrough in the history of our field has taken occurred due to the ingenious step to invent a new technique.

With the rapid development of science and technology, oral and maxillofacial reconstructive surgery has kept pace with time to bring a prosperous future. OMS reconstructive surgery was focused on with major achievements made in the following aspects: transplantation of revascularized tissues, bone graft substitutes, platelet-rich plasma, tissue

Copyright © 2021 The Author(s): This is an open-access article distributed under the terms of the Creative Commons Attribution 4.0 International License (CC BY-NC 4.0) which permits unrestricted use, distribution, and reproduction in any medium for non-commercial use provided the original author and source are credited.

engineering, distraction osteogenesis, microsurgery, arthroplasty, dynamic repair, lazer surgery, computer-assisted design.

Microvascular tissue transfer was one of the most important stages in the reconstruction of the lower jaw and upper jaw after ablative tumor surgery. Modern methods using a vascularized composite fibula flap together with dental implants have led to successful rehabilitation in terms of speech, mastication and facial esthetics.

In tissue engineering, cells, stimulatory factors (growth factors) and scaffold materials as the three main factors, provide the opportunity to create various tissues and organs with their forms and functions by changing combinations of these three factors.

The use of three-dimensional printing (3D) application technology in maxillofacial surgery include trauma surgery, pathology induced defects, complex temporomandibular joint reconstruction and correction of complicated facial asymmetry.

Prerequisites for three-dimensional (3D) visualization and programs for computer-assisted 3D planning of surgical procedures have been established. There is an increasing use of 3-dimensional (3D) imaging applications for pre-surgical planning and transfer of oral implant treatment.

The effectiveness of the navigation system for oral and maxillofacial surgery has been confirmed by clinical applications including complex fractures of the middle and facial region, reconstruction of orbital trauma, removal of a foreign body, surgery based on the skull, orthognathic surgery and provides more safe and accurate guidance in the field of maxillofacial surgery.

Preoperative surgical simulations with 3D models, such as stereo lithographic models, are useful to evaluate treatment plans and to acquire precise representations of the underlying skeletal anatomy of the patient.

In this digital age, we have also embraced the revolutionary changes that modern computer technologies have brought to our field. From anatomical scans using imaging techniques such as Magnetic Resonance Imaging (MRI) and Computed Tomography (CT) scans, computer-aided design/computer-aided manufacturing to surgical navigation to robotic surgery. Transoral robotic surgery is also gathering steam with the prospects of offering surgeons greater precision, sensitivity and flexibility to overcome challenges associated with conventional approaches.

Computer-aided surgery has gradually become an indispensable part of our modern practice-one with greater accuracy, safety and simplicity. Computer-assisted navigation has gained acceptance in maxillofacial surgery with application in an increasing range of procedures.

The development of navigation assisted surgery has improved execution and predictability, allowing for greater precision during oral and maxillofacial surgery.

The use of a navigation system for osteotomy and resection in tumor surgery, particularly at the skull base, allows the procedure to be performed more quickly, safely, and precisely. The use of navigation for areas where surgical approaches are difficult and areas requiring anatomical attention provides confidence in the approach. In the near future, the application of computer-assisted surgery is expected to further reduce operative risks and time, accompanied with a considerable decrease in patient stress. Therefore, the use of a navigation system will also be effective and feasible in oral and maxillofacial surgery [2].

USE OF VISUAL AIDS IN IMPROVING CONSENT IN MAXILLOFACIAL SURGERY

The relaying of accurate information to head and neck patients in the pre-operative setting is integral step in gaining informed consent in surgery. Evidence suggests that medical professionals are often poor at conveying information to patients and relatives – particularly so for complex surgical procedures. Visual aids have been shown to aid the consent process – improving the understanding and retention of areas discussed during the clinical consultation in addition to an inferred improvement in patient outcomes and lower post-operative risk of complications. Current cross-sectional imaging modalities can often be challenging for patients to visualise and interpret. The use of 3D printed models can often help demonstrate the size and extent of bone pathology but lack the ability to clearly depict soft tissue lesions. To enhance this process we describe a method which provides a visual adjunct to the consent process to improve patients understanding of the diagnosis and surgical plan. The technique incorporates the use of Mimics inPrint© (Materialise, Belgium) to produce a 3D printed model of a patient's skull and pathology in combination with Ufi gel (VOCO GmbH) (a pink denture soft liner material) which, when cured, can be used to accurately show the size, extent and location of the soft tissue pathology. The initial step of the technique (in this case a large dentigerous cyst occupying

the left hemi maxilla) utilises edit tools found within Mimics in Print software allow the target pathology to be identified segmented from the computerised tomography (CT) scan [3].

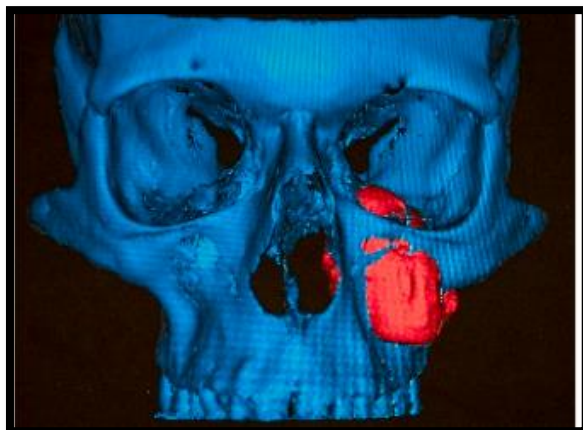


Fig 1: Computer generated image from the CT scan

The target pathology model is then copied using recognised Maxillofacial laboratory techniques and replaced using Ufi gel forming a hollow copy that can be inserted into the hard tissue model.

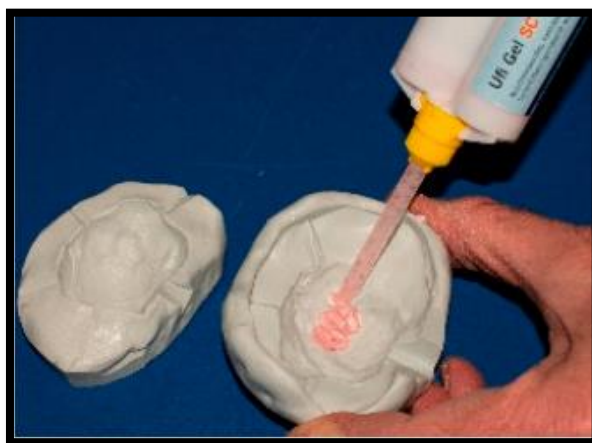

Fig 2: A mould is made of the 3D printed lesion using silicone that is then lined with Ufi gel

The flexible and contrasting coloured copy (Fig 3) can then be inserted into the 3D skull model easily to create the final model (Fig 4).

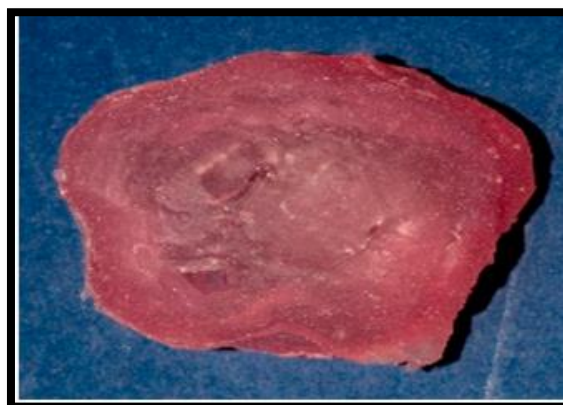

Fig 3: The lesion is now represented in the added to the 3D printed skull, creating the final model

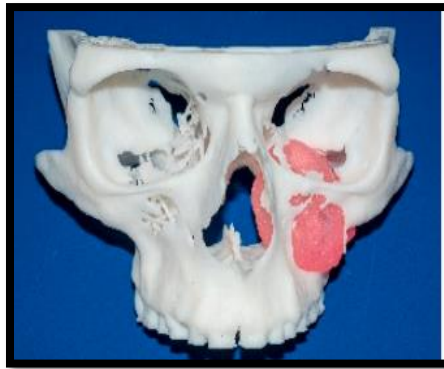

Fig 4: The Ufi gel lesion is flexible Ufi gel format

The Ufi gel is instrumental in visually showcasing the pathology and conveys the information in a tactile and interactive manner to patients. The contrasting colour also allows patients to clearly visualise the clinical problem and provides a platform for the operating surgeon in explaining and outlining any proposed treatment. Having a local point of care printing hub at the Royal Derby Hospital producing the 3D models allows for added collaboration between the Maxillofacial Surgeon and the Maxillofacial Prosthetist/Reconstructive Scientist to assess the underlying pathology and plan surgery at minimal cost [3].

Negative Pressure Wound Therapy in Maxillofacial Applications

Negative pressure wound therapy (NPWT) is the application of a continuous or intermittent subatmospheric pressure to a localized wound environment using a topical negative pressure dressing (TNPD) connected to a vacuum pump. TNPD are typically open-cell reticulated foams, polyurethane or other material, or gauze-based vacuum dressing. NPWT is also known as subatmospheric pressure (SAP), topical negative pressure (TNP), vacuum-assisted closure (V.A.C.), and microdeformational wound therapy (MDWT), and has greatly impacted the field of wound and surgical care over the past nearly 20 years. NPWT has been used extensively in the treatment of acute and chronic wounds on the torso and limbs, and has been used to treat diabetic foot ulcers. However, NPWT has been underutilized in head and neck surgeries, despite several case studies showing safe and effective use of NPWT. The current manuscript will briefly review the history of wound healing, the basic science behind NPWT, the considerations for maxillofacial applications, and future improvements for NPWT [4].

- Wound Healing

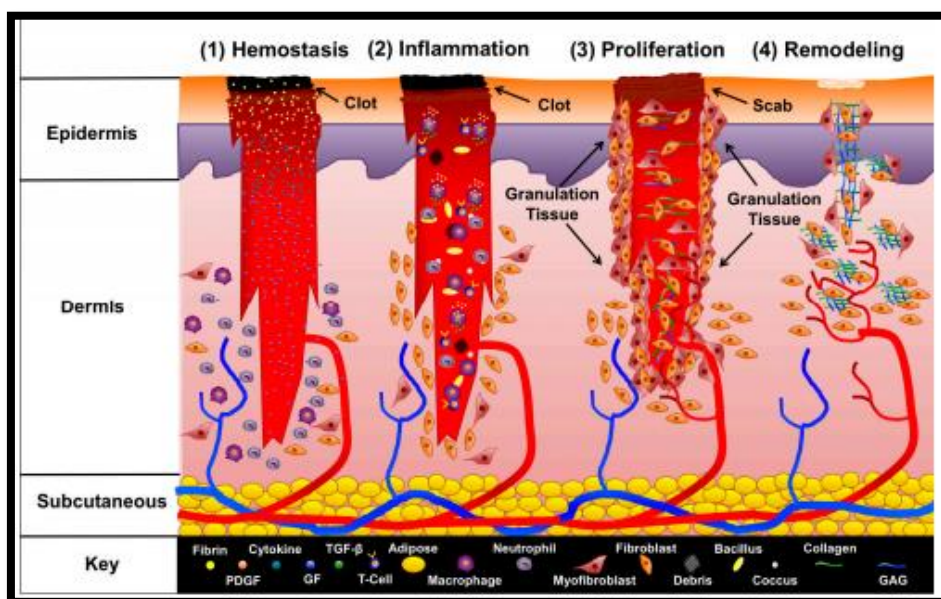


Figure 1: Phases of wound healing

- Wound Dressings
- Vacuum Assisted Closure

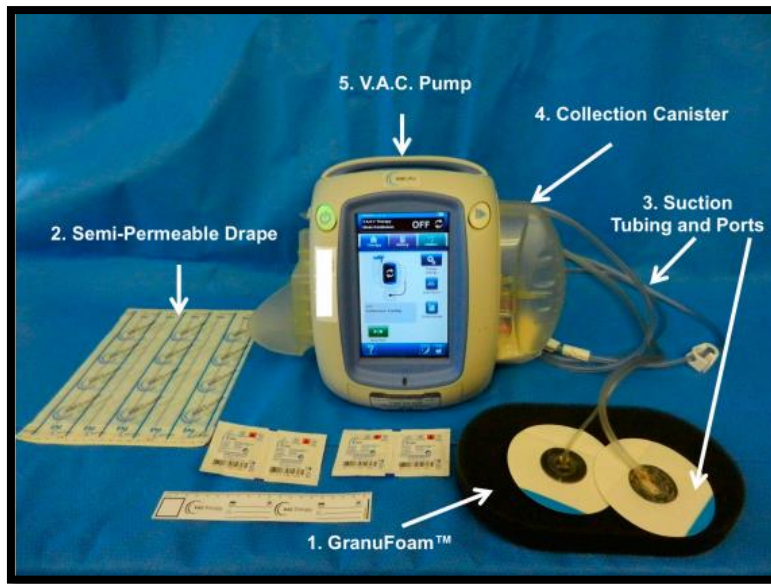
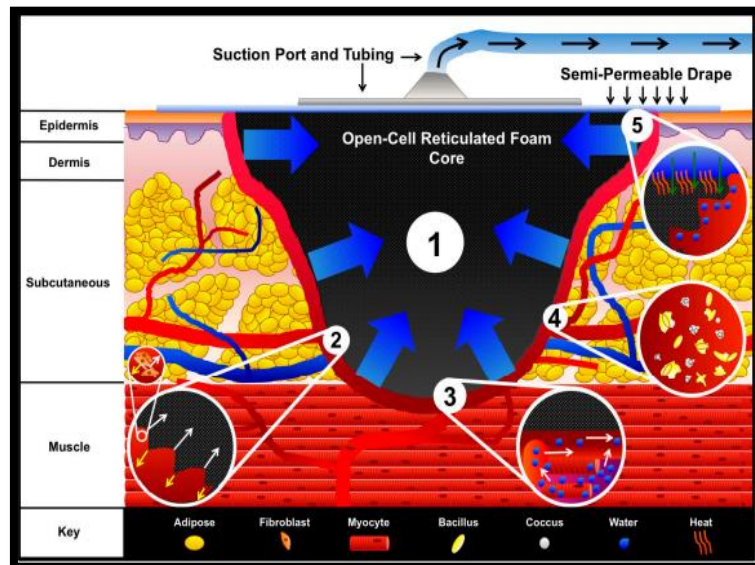


Figure 2: Vacuum Assisted Closure (V.A.C.) system



V.A.C. mechanisms of action

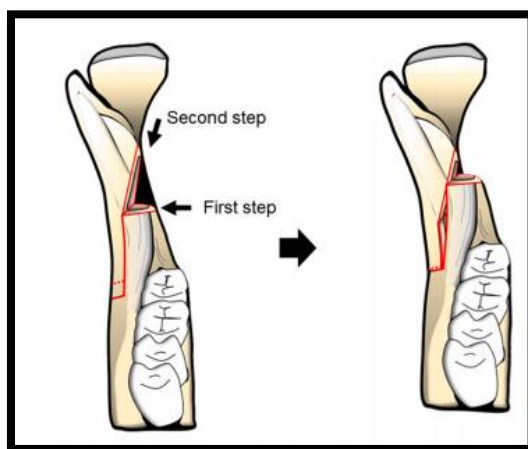
- **Macrostrain**
- **Microstrain**
- **Fluid Removal and Edema Reduction**
- **Reduction of Infectious Material**
- **Wound Stabilization and Secondary Events**

MAXILLOFACIAL CONSIDERATIONS

The head and neck provides many unique problems to maxillofacial surgeons in the setting of wound healing and reconstruction. Function and aesthetics are often equally important to most patients. Simultaneous management of both function and aesthetics has driven a large market for products such as TNPDs used in NPWT. Use of NPWT as a surgical adjuvant in maxillofacial surgery was first described in 2006. This paper retrospectively reviewed the use of NPWT in several complicated maxillofacial situations, such as exposed calvarial bone, bolster dressing for large facial skin grafts, and wound management following necrotizing fasciitis debridement. NPWT was successful in all such clinical situations and this work led to other published reports that expanded its use. Palm *et al.* reviewed 1502 peer-reviewed journal articles on “vacuum therapy” for which 37 articles pertained to maxillofacial surgery. They noted that studies were generally limited by containing case reports or case series and NPWT was used as an adjuvant maxillofacial reconstructive procedures and management of soft tissue defects of the neck. However, published reports on NPWT use

are in all areas of maxillofacial reconstruction. The largest study by Satteson *et al.*, reviewed 69 patients with 73 head and neck wounds resulting from cancer (86%), trauma (8%), infection (3%), or burns (3%) that used V.A.C. in conjunction with skin grafts, Integra, and open debrided wounds. Minor complications were reported in 56% of patients that received skin grafts, 33% of patients that received Integra, and 29% of patients with open debrided wounds. Most complications were resolved with follow-up treatment. Upper Third Maxillofacial Reconstruction NPWT use for scalp and forehead reconstruction was first described by Andrews *et al.* Its use for skin and soft tissue defects has been further described by Hsia *et al.* Both studies demonstrated that NPWT could be used to temporize wounds in the setting of trauma and contamination or definitively treat wounds by promoting granulation tissue formation and wound contracture/epithelialization. More aggressive protocols have been used to manage exposed dura and/or brain when the calvarium is missing. Ahmed *et al.*, discussed technical nuances to manage cerebrospinal fluid (CSF) compartmentalization and eventual soft tissue coverage of dural repairs in their case report. Middle Third Maxillofacial Reconstruction Soft tissue defects of the cheeks and orbit are particularly suitable for NPWT. NPWT can be used to promote granulation tissue formation on the facial skeleton so that skin grafts can be applied, for wound management and contracture, or for skin graft bolstering. Although these applications seem straightforward concerns arise in the midface maintaining an occlusive seal of any negative pressure device secondary to the midface contours and the presence of the eyes, nose, mouth and ears. Lower Third Maxillofacial Reconstruction NPWT use on the lower jaw and its soft tissue has been well described. Zhang *et al.*, described its use in the management of submandibular fistulas after osteoradionecrosis reconstruction. In their study NPWT was successful closing small submandibular fistulas that developed in nine patients in 7 to 12 days. The proximity of the oral cavity and often a tracheostomy make utilization of NPWT in this region difficult. Neck Reconstruction Cutaneous-oral fistulas are a rare and difficult complication of maxillofacial surgery. TNPDs have been shown to be an effective means of closing these intraoral communications. Long track fistulas with collapsible non-radiated tissues have been shown to be most amenable to this mode of closure. Yang *et al.* used TNPDs to successfully close eight salivary fistulas with an average time of treatment being 10.8 days. Tian *et al.* further advanced the utilization of TNPD for salivary fistula closure by employing dental paste intraorally to maintain an occlusive seal for the negative pressure system. In their series, they successfully close salivary fistulas in 9 of 10 patients [4].

TRIANGULAR-SHAPED LINGUAL OSTEOTOMY USING A BONE SAW IN SAGITTAL SPLIT RAMUS OSTEOTOMY



Schematic diagram of triangular-shaped lingual osteotomy. Using a bone saw, sufficient space was acquired easily and safely, and the distal segment was able to be moved about three-dimensionally [5]

IMAGE-GUIDED NAVIGATION IN ORAL AND MAXILLOFACIAL SURGERY

With the increasing sophistication of imaging techniques, the scope of surgical practice is expanding. The next advance is the integration of imaging with the surgical field, which will allow visualisation of different types of image simultaneously, show structures that are normally only visible intraoperatively, and permit intraoperative navigation in areas of anatomical sensitivity. This will enable with the increasing sophistication of imaging techniques, the scope of surgical practice is expanding. The next advance is the integration of imaging with the surgical field, which will allow visualisation of different types of image simultaneously, show structures that are normally only visible intraoperatively, and permit intraoperative navigation in areas of anatomical sensitivity. This will enable preoperative surgical planning to be incorporated directly into the procedure. Other clinical benefits of image-guided surgery may also evolve with the use of smaller incisions, direct access to specific targeted areas, and consequently less invasive operations [6].

CONCLUSION

OMS is, in itself, an integral field that encompasses aspects of science, clinical techniques and esthetics. A review of recent progress in our field reveals the importance of an active and critical scholarly forum that allows the development of revolutionary concepts and innovative ideas such as functional and minimally invasive surgical approaches as well as the computer-aided surgical techniques. The development of oral and maxillo-facial surgical technique is still constantly evolving and we sincerely hope that our special issue keeps up with the waves of change.

REFERENCES

1. Balasundaram, I., Al-Hadad, I., & Parmar, S. (2012). Recent advances in reconstructive oral and maxillofacial surgery. *British Journal of Oral and Maxillofacial Surgery*, 50(8), 695-705.
2. Hakobyan, G. (2020). New Trends Oral and Maxillofacial Surgery Past Two Decades. *J Surg Curr Trend Innov S1: 006*. Received: May, 13.
3. Ayub, M., Patel, D., Thorpe, R., Jones, J. L., & Jones, K. (2021). Use of visual aids in improving consent in Maxillofacial Surgery: a novel technique. *Advances in Oral and Maxillofacial Surgery*, 100107.
4. Mellott, A. J., Zamierowski, D. S., & Andrews, B. T. (2016). Negative pressure wound therapy in maxillofacial applications. *Dentistry journal*, 4(3), 30.
5. Kita, R., Yoshino, A., Mano, R., Nakamura, S., & Kondo, S. (2021). WITHDRAWN: Triangular-shaped lingual osteotomy using a bone saw in sagittal split ramus osteotomy. *Advances in Oral and Maxillofacial Surgery*, 3, 100133.
6. Nijmeh, A. D., Goodger, N. M., Hawkes, D., Edwards, P. J., & McGurk, M. (2005). Image-guided navigation in oral and maxillofacial surgery. *British Journal of Oral and Maxillofacial Surgery*, 43(4), 294-302.

Citation: Sandeep Kumar Sharma *et al* (2021). Recent Advances in the Field of Reconstruction in Oral & Maxillofacial Surgery. *South Asian Res J Oral Dent Sci*, 3(6), 131-137.