

Case Report

Acantholytic Acanthoma in the Oral Mucosa

Laura Fernández-Cuevas¹, Gisela Navarrete-Franco², Maribet González-González², Alba Cicero-Casarrubias³, Lilly Esquivel-Pedraza^{4*}

¹Oral Pathology Clinic, Centro Dermatológico 'Dr. Ladislao de la Pascua', Mexico City, Mexico

²Dermatopathology Department, Centro Dermatológico 'Dr. Ladislao de la Pascua', Mexico City, Mexico

³Immunology and Rheumatology Department, Instituto Nacional de Ciencias Médicas y Nutrición 'Salvador Zubirán', Mexico City, Mexico

⁴Dermatology Department, Instituto Nacional de Ciencias Médicas y Nutrición 'Salvador Zubirán', Mexico City, Mexico

*Corresponding Author

Lilly Esquivel-Pedraza

Article History

Received: 11.07.2021

Accepted: 16.08.2021

Published: 18.08.2021

Abstract: *Background:* Acantholytic acanthoma is a rare benign condition of the skin, commonly solitary, with keratotic surface and a papular or nodular appearance, it is typically asymptomatic, and affects most frequently the trunk. *Main observations:* In this manuscript we describe an extraordinary case of an acantholytic acanthoma associated to fibrous hyperplasia involving the oral mucosa. *Conclusions:* We present an exceptional case; to our knowledge, no cases of acantholytic acanthoma affecting oral mucosal membranes have been previously reported in the literature.

Keywords: Mouth diseases, acantholytic acanthoma, oral mucosa.

INTRODUCTION

Acantholytic acanthoma is a rare benign condition in which acantholysis of squamous epithelium is the most remarkable histological feature [1]. This tumor has previously been reported as an entity that exclusively affects the skin [1-4]. Thus, the purpose of this paper was to describe an unusual acantholytic acanthoma located in the mouth, this case was seen at a national dermatology referral center in Mexico City.

CASE REPORT

A 44 year-old woman was seen at the Oral Pathology Department of the Centro Dermatológico 'Dr. Ladislao de la Pascua' in February 2012, due to the presence of a small asymptomatic nodule on the tongue, first noticed on December 2009. The lesion was initially excised by a general physician on May 2011 and previously diagnosed microscopically as fibrous hyperplasia. The patient described that the lesion recurred shortly after the biopsy, the lesion had the same clinical features than the previous one, but it grew faster.

At oral examination, a single asymptomatic, soft nodule (sized 5x5x4 mm) on the tip of the tongue, covered by normal mucosa was observed (Fig.1A & B). Medical history of patient and her family was unremarkable. The lesion was completely excised.

The specimen was fixed in formalin, processed with hematoxylin and eosin staining, and submitted to histopathological examination, which revealed hyperkeratosis of the epithelium with a prominent acantholysis involving all its layers, as well as papillomatosis, mild perivascular lymphocytic infiltrate and slight fibrosis of connective tissue (Fig. 2A-C). The diagnosis of acantholytic acanthoma was established. After two years of follow-up, no recurrence of the lesion was observed (Fig.1C).

Copyright © 2021 The Author(s): This is an open-access article distributed under the terms of the Creative Commons Attribution 4.0 International License (CC BY-NC 4.0) which permits unrestricted use, distribution, and reproduction in any medium for non-commercial use provided the original author and source are credited.

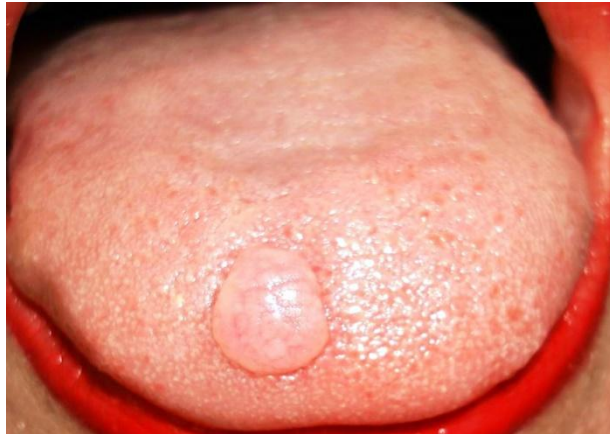

Figure1A: Asymptomatic nodule on the dorsum of the tongue. Note the punctiform papules on the nodule

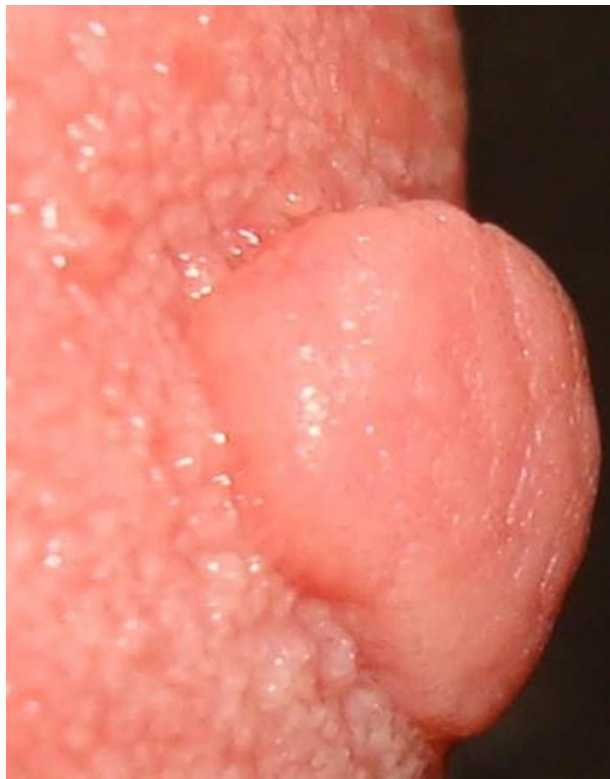

Figure 1B: Close up profile of a pedunculated nodule with smooth surface on tip of the tongue

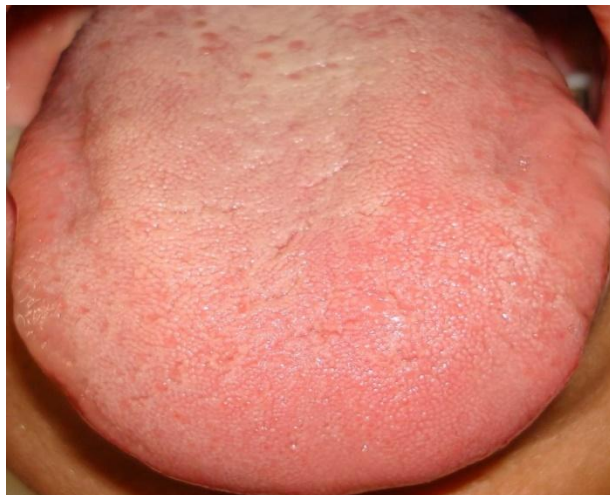

Figure 1C: Clinical image two years after surgery. Note the clinically normal aspect of the tongue surface

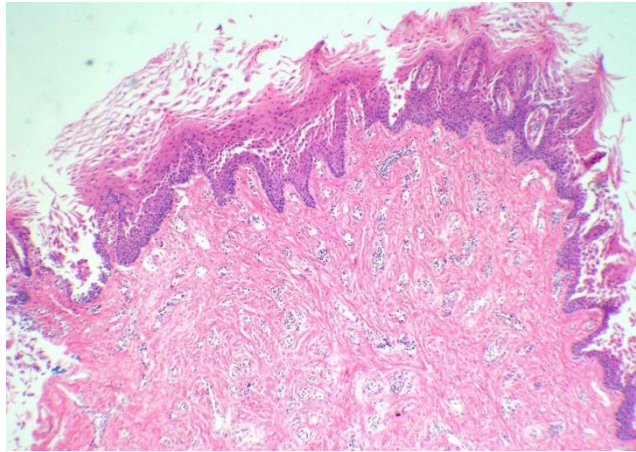


Figure 2A: Panoramic view of the fibrous hyperplasia with parakeratosis and hyperkeratosis & acantholysis of the epithelium (Hematoxylin and eosin stain, 4x)

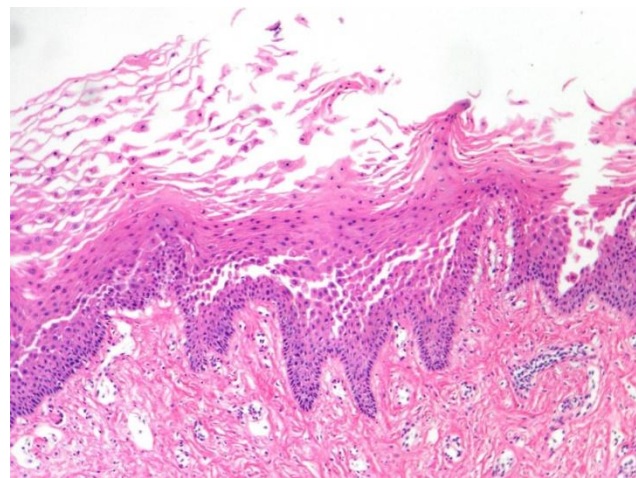


Figure 2B: Separation of the prickle cell layer from the epithelium. (Hematoxylin and eosin stain, 10x)

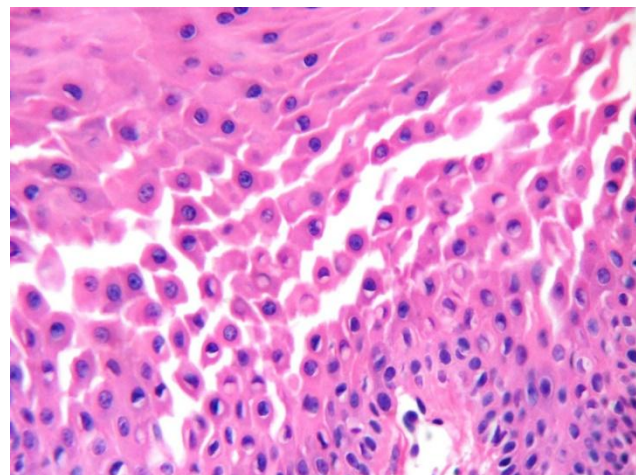


Figure 2C: High power view of the acantholytic cells in the stratum spinosum of the epithelium (Hematoxylin and eosin stain, 40x)

DISCUSSION

Acantholytic acanthoma is a cutaneous condition, described in 31 subjects by Michael Brownstein in 1988 [1]. Most of the cases were seen in patients over 50 years and they were slightly more frequent in males (ratio 2:1). Until now, 36 cases have

been reported, including a case in an immunosuppressed patient [3-5] and two patients with cutaneous malignant neoplasms [3, 5].

The tumour affects most commonly the trunk, but other anatomical sites such as limbs and neck can be involved [1]. To our knowledge, no reports of

acantholytic acanthoma affecting the mouth have been described. Thus, this is the first reported case of acantholytic acanthoma located in oral mucosa.

The etiology and pathogenesis of acantholytic acanthoma are unknown; but a traumatic origin has been proposed. In this case, the lesion developed in a highly traumatic intraoral location with history of previous local surgery trauma when first removed; however, if frictional forces were the cause of acantholytic acanthoma, this condition should be observed with certain frequency in mouth mucosa, while this site supports trauma constantly. Another hypothesis suggests the role of decreased immune surveillance, due to a case with multiple lesions in an immunocompromised patient [4] and in cancer subjects [3, 5]. In our patient, no immunosuppression was documented.

Acantholytic acanthoma is commonly a solitary, hyperkeratotic and occasional crusting cutaneous tumor, with papular appearance, usually asymptomatic; also, a molluscum contagiosum-like presentation due to central umbilication has been noted [2, 6]. The differential diagnosis of acantholytic acanthoma in skin includes seborrheic keratosis, actinic keratosis, basal cell carcinomas [1]. In this case, fibrous hyperplasia, granular cell tumour, focal epithelial hyperplasia, among other diagnoses, should be considered in the mouth. Histologically, prominent acantholysis of the epidermis is the hallmark of acantholytic acanthoma and should exclude other conditions such as pemphigus, Grover's disease, Hailey-Hailey disease, and stain artifact, predominantly [1, 6-8].

Oral fibrous hyperplasia is a very common intraoral lesion, mainly located on the tongue. The lesion typically presents as a smooth-surfaced nodule that is similar in color to the surrounding mucosa and it is usually asymptomatic. Occasionally, the surface of fibrous hyperplasia is covered by a whitish plaque of hyperkeratosis, due to persistent trauma. Most lesions of fibrous hyperplasia are sessile, although some are pedunculated. Our case of acantholytic acanthoma on the tip of the tongue was clinically indistinguishable from lingual fibrous hyperplasia; in fact, this was our original presumptive diagnosis previous to microscopic examination. Moreover, the histological diagnosis of the first removed lesion was fibrous hyperplasia. In the second developed lesion, the striking finding was the presence of acantholytic acanthoma on a fibrous hyperplasia.

Some cases of fibrous hyperplasia in the mouth are frequently diagnosed only on a clinical basis and are not removed, mainly due to absence of symptoms and benign behavior; also, when tissue is removed, material is frequently not submitted to histopathological examination and this is a common practice among dentistry. Our case remarks the significant importance of microscopic examination of every excised lesion.

CONCLUSIONS

This is a rare case of acantholytic acanthoma in mouth mucosa associated with fibrous hyperplasia. This case underlines the relevance of microscopic study and opens the possibility of considering mouth as a site for such lesion.

ACKNOWLEDGEMENTS

The authors would especially like to thank Obdulia Rodríguez-Rodríguez, M.D., for revision of the final version of this manuscript.

REFERENCES

1. Brownstein, M. H. (1988). Acantholytic acanthoma. *Journal of the American Academy of Dermatology*, 19(5), 783-786.
2. Barnette, D. J., & Cobb, M. (1995). A Solitary, Erythematous, Hyperkeratotic Papule. *Archives of Dermatology*, 131(2), 213-214.
3. Kim, S. H., Choi, J. H., Sung, K. J., Moon, K. C., & Koh, J. K. (2000). Acantholytic acanthoma. *The Journal of Dermatology*, 27(2), 127-128.
4. Ramos-Caro, F. A., Sexton, F. M., Browder, J. F., & Flowers, F. P. (1992). Acantholytic acanthomas in an immunosuppressed patient. *Journal of the American Academy of Dermatology*, 27(3), 452-453.
5. Megahed, M., & Scharffetter-Kochanek, K. (1993). Acantholytic acanthoma. *The American journal of Dermatopathology*, 15(3), 283-285.
6. Cho, S., Lee, H. K., & Song, K. Y. (2007). Acantholytic acanthoma clinically resembling a molluscum contagiosum [11]. *Journal of the European Academy of Dermatology and Venereology*, 21(1), 119-120.
7. Minakawa, S., Matsuzaki, Y., Nakano, H., Sawamura, D., & Elenitsas, R. (2012). Acantholysis caused repeated hemorrhagic bullae in a case of acantholytic acanthoma. *The Journal of Dermatology*, 12(39), 1107-1108.
8. Bindhu, P. R., Krishnapillai, R., Thomas, P., & Jayanthi, P. (2013). Facts in artifacts. *Journal of Oral and Maxillofacial Pathology: JOMFP*, 17(3), 397-401.

Citation: Laura Fernández-Cuevas *et al* (2021). Acantholytic Acanthoma in the Oral Mucosa. *South Asian Res J Oral Dent Sci*, 3(4), 95-98.