

Case Report

Surgical Removal of Epidermoid Cyst of Forehead...Limitless Borders for Maxillofacial Surgeons- A Case Report

Soumendu Karak^{1*}, Shishir Mohan Devki², Shaivy Ambuj³

¹Post Graduate Student; Department of Oral & Maxillofacial Surgery; K.D.Dental College & Hospital Uttar Pradesh India

²Prof. & Head of the Department; Department of Oral & Maxillofacial Surgery; K.D.Dental College & Hospital Hospital Uttar Pradesh India

³Post Graduate Student; Department of Prosthodontics and Crown & Bridge; K.D.Dental College & Hospital Hospital Uttar Pradesh India

***Corresponding Author**

Soumendu Karak

Article History

Received: 30.09.2020

Accepted: 22.10.2020

Published: 30.10.2020

Abstract: An epidermoid cyst or epidermal inclusion cyst is a benign cyst usually found on the skin. The slow growing benign cysts develop out of ectodermal tissue. Epidermoid cyst may have no symptoms, or it may be painful when touched and release macerated keratin. The treatment of epidermoid cyst is surgical removal with entire removal of capsule to minimize the recurrence or minimize the chance of malignant transformation. Here we report a case of a 64 year male old patient with epidermoid cyst in forehead, total surgical resection of the cyst was done in department of Oral and Maxillofacial Surgery in K.D. Dental College and Hospital with optimal exposure to avoid recurrence.

Keywords: Epidermoid cyst, total surgical resection.

INTRODUCTION

Epidermoid cyst is considered a benign lesion and usually affect the scalp regions, face, neck back or torso [1]. The slow growing benign cysts develop out of ectodermal tissue. Epidermoid cyst may have no symptoms, or it may be painful when touched. Epidermoid cysts commonly result from implantation of epidermis into the dermis, as in trauma or surgery. They can also be caused by a blocked pore adjacent to a body piercing. Epidermoid cysts have prevalence for males and are seen in Gardner's syndrome and Nevoid basal-cell carcinoma syndrome.

Surgical resection is the only effective treatment, but the debate is still open regarding the advantages of a total resection versus a decompression procedure with subtotal resection [2].

CASE REPORT

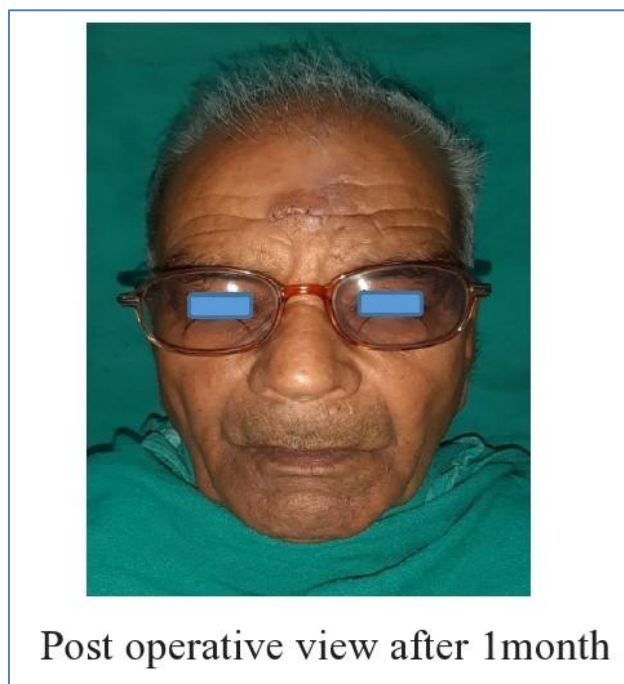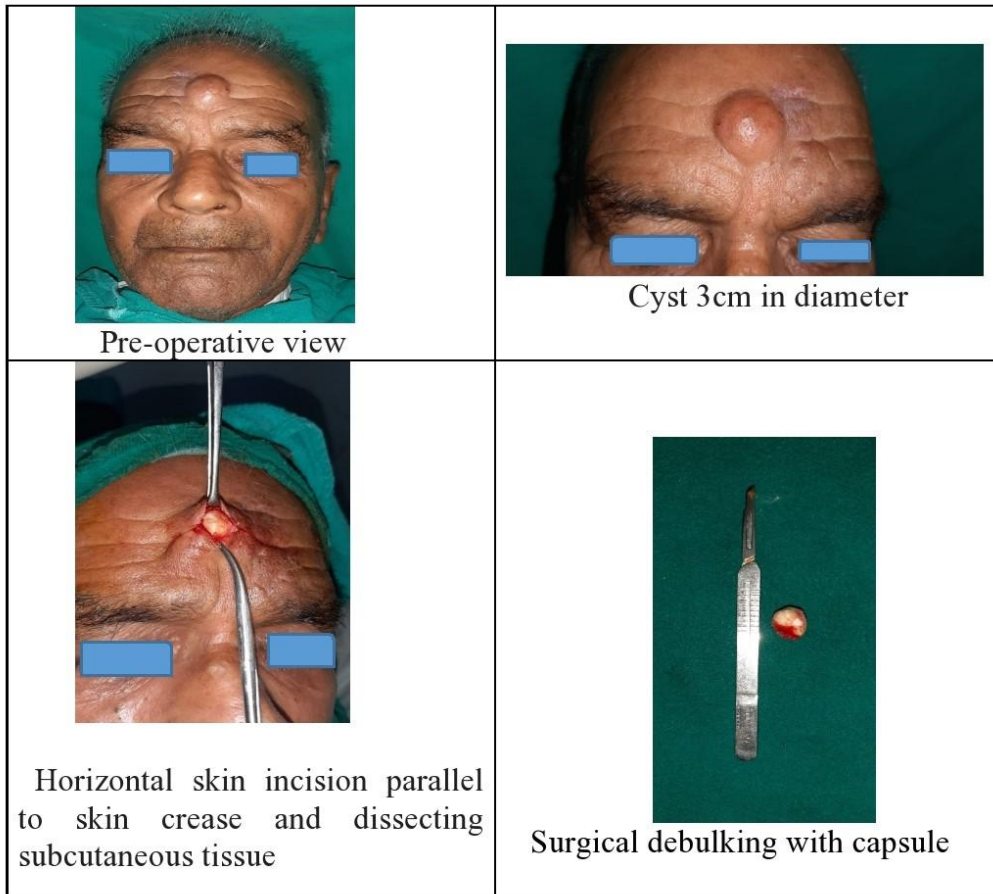
A 64 year old male patient reported to the department of Oral and Maxillofacial Surgery, K.D.Dental College and Hospital, Mathura with painless ovoid gradually progressive and persistent swelling on mid forehead region since 10 years. On clinical examination swelling was found about 3cm in diameter, well defined and firm on palpation. Patient had decided to seek expert help mainly for esthetic purpose. Computed tomographic scan and FNAC were performed. CT scan revealed 28x26x10mm large encapsulated homogenous extracranial mass in mid-forehead region. FNAC cytology revealed pultaceous material with presence of fat and no malignancy criteria.

Surgical debulking with capsule was planned, though it was a great challenge as esthetic was main concern of patient, also care had to be taken as cyst spillage may cause secondary infection (into intracranial space may cause meningitis) or limited resection causes higher risks of recurrence or chance of malignant transformation.

Copyright © 2020 The Author(s): This is an open-access article distributed under the terms of the Creative Commons Attribution 4.0 International License (CC BY-NC 4.0) which permits unrestricted use, distribution, and reproduction in any medium for non-commercial use provided the original author and source are credited.

Horizontal skin incision was given parallel to hairline. After dissecting subcutaneous tissue, encapsulated cyst was removed very gently and sent for histological examination. Anterior table of frontal bone was curette very cautiously to remove any residue. Gelfoam was placed in dead space and subcutaneous suture was placed along the skin crease.

Histopathological examination showed cystic lumen lined by orthokeratinized stratified squamous epithelial cell suggestive of epidermoid cyst.



DISCUSSION

Development of epidermoid cyst is multifactorial, but inclusion of ectodermal tissue into the skull during embryogenesis is one main hypothesis [3]. It may arise secondary to trauma and may undergo malignant transformation [4]. In our case we were not sure the actual cause of cyst, as there was no history of trauma it might be a possible congenital variety. There were no clinical signs of infection or malignant condition. Thorough physical examination and FNAC, helped us to rule out this with other pathological conditions like lipoma, salivary vascular lesion etc.

In consideration of the higher morbidity of recurrent epidermoid cyst, the latest studies take the view that total resection is associated with improved function and low mortality and should be recommended as the ideal goal of treatment[5, 6].

CONCLUSION

In the surgical point total debulking of epidermoid cyst with capsule is a challenging especially when patient is more anxious for esthetic though it dramatically reduces the risk of recurrence and malignant transformation.

Declaration of Patient Consent

The authors certify that they have obtained all appropriate patient consent forms. In the form the patient has given his consent for his images and other clinical information to be reported in the journal. The patient understands that his name and initials will not be published and due efforts will be made to conceal their identity, but anonymity cannot be guaranteed.

Conflicts of interest

There are no conflicts of interest

REFERENCES

1. de Mendonça, J. C. G., Jardim, E. C. G., dos Santos, C. M., Masocatto, D. C., de Quadros, D. C., Oliveira, M. M., ... & Teixeira, F. R. (2017). Epidermoid cyst: clinical and surgical case report. *Annals of Maxillofacial Surgery*, 7(1), 151.
2. Antonella, M., Edoardo, M., Alessandro, I., Cosimo, S., Alessio, A., Enrico, M., Alessandro, O., Alfredo, P., & Carmelo, L. S. (2018). Surgical Management of Intracranial Giant Epidermoid Cysts in Adult: A Case-Based Update. *Asian J Neurosurg*, 13(4): 1288–1291.
3. Shashikant, A.P., Arjun, D. (2018). Nitin Gupta and Aditi Mahajan. Extradural Epidermal Inclusion Cyst of Forehead: Case Report. *J Head Neck Spine Surg*, 3(4): 555619.
4. Ciappetta, P., Artico, M., Salvati, M., Raco, A., Gagliardi, F.M. (1990). Intradiploic epidermoid cysts of the skull: report of 10 cases and review of the literature. *Acta Neurochir (Wien)*; 102(1-2):33-7.
5. Aboud, E., Abolfotoh, M., Pravdenkova, S., Gokoglu, A., Gokden, M., Al-Mefty, O. (2015). Giant intracranial epidermoids: is total removal feasible? *Journal of neurosurgery*, 122:743–56.
6. Safavi-Abbasi, S., Di Rocco, F., Bambakidis, N. (2008). Has Management of Epidermoid Tumors of the Cerebellopontine Angle Improved? A Surgical Synopsis of the Past and Present. *Skull Base*, 18(2):85–98.