

Comparative Morphological Evaluation of Male Rabbit (*Oryctolagus cuniculus*) Testis between Immature and Mature Stage

Hussam Khudhair Obais^{1*}, S. M. Alkafagy²

¹Department of Anatomy and Histology, Veterinary Medicine College, Al-Qasim Green University, Babylon 51013, Iraq

*Corresponding Author: Hussam Khudhair Obais

Department of Anatomy and Histology, Veterinary Medicine College, Al-Qasim Green University, Babylon 51013, Iraq

Article History: | Received: 26.03.2026 | Accepted: 19.05.2026 | Published: 22.05.2026 |

Abstract: The present study was designed to describe of the morphological, histological, and immunohistochemical changes of the testis in local male rabbits (*Oryctolagus cuniculus*) postnatal period at age immature (45day), and mature(150day) with special emphasis on immunohistochemical-related components. This study was investigated to study the development of testis during postnatal periods. Thirty of male rabbit (*Oryctolagus cuniculus*) of postnatal period in two age (45 days immature and 150 days mature), were used in this study. Samples were collected by purchasing them from veterinary clinics. They were admitted to the university (Al - Qasim Green University) animal house and monitored for good health for 15 days. Morphological study 10 rabbits, histological study 10 rabbits and immunohistochemistry 10rabbits (5for each age). The rabbits were then placed on the dissection stage after anesthesia. The weights of the rabbits were measured using an electronic balance. The rabbits were in good health, and the testicles were cut in the perineum after dissection. nAt age immature (45 day) the testis of male rabbits (*Oryctolagus cuniculus*) showed that located intra-abdominally on both sides near the kidneys, and the scrotum was not clearly developed. The testes appeared curved and elongated in shape with a dark brown coloration. Morphometrically, differences were observed between the left and right testes. The mean weight of the left testis was low with noticeable variation, while the right testis showed a lower mean weight with slight variation. The mean length of the left testis was greater with small variation, compared with a shorter length with small variation for the right testis. The mean width was larger with minimal variation for the left testis and smaller with minimal variation for the right testis.

Keywords: Testis, Cat, Morphological, Color, Location.

Copyright © 2026 The Author(s): This is an open-access article distributed under the terms of the Creative Commons Attribution 4.0 International License (CC BY-NC 4.0) which permits unrestricted use, distribution, and reproduction in any medium for non-commercial use provided the original author and source are credited.

INTRODUCTION

Rabbits are small mammals in the family Leporidae of the order Lagomorpha, found in various parts of the world. There are eight different genera in the family classified as rabbits, such as the European rabbit (*Oryctolagus cuniculus*); cottontail rabbits (genus *Sylvilagus*) and Amami rabbit (*Pentalagus furnessi*) and others. The male is called a buck, and the female is a doe; a young rabbit is a kitten or kit. (Hussein and Abass (2015).

The testes are the primary organs of reproduction in the male. They produce spermatozoa sperm and hormones (androgens), which affect reproductive function and behavior. The testes are important sacs of coiled tubules within which the sperm

are formed. This process known as spermatogenesis, which involves changes from a rather normal-looking spheroidal cell into the highly specialized spermatozoon. These controlling hormones regulate the levels of the to some extent in sperm storage. The accessory sex glands normally add their secretions to the semen at or near the junction of the deferent ducts and the urethra. Lefèvre *et al.*, (2021) Testis is a part of the male genital organs in mammals, most of which is controlled by seminiferous tubular tissue (Caldeira *et al.*, 2010).

MATERIAL AND METHOD

To investigate gross morphological disruption of male Rabbit (*Oryctolagus cuniculus*) testis, we used ten male rabbit (5 premature and 5 mature). And then synthesized these animals by intramuscular injection of

Citation: Hussam Khudhair Obais & S. M. Alkafagy (2026). Comparative Morphological Evaluation of Male Rabbit (*Oryctolagus cuniculus*) Testis between Immature and Mature Stage, *SAR J Anat Physiol*, 7(3), 35-40.

ketamine and xylazine, after completing fixed the animal on anatomical board and making longitudinal incision on the scrotum to get the testis. The morphological parameters were recorded (length, weight, thickness, width) by using the electron Vernia and sensitive balance. The shape and color were recorded and took photographs.

RESULT AND DISCUSSION

The morphological result of male rabbit reproductive relevant that the testis was occupied by scrotum, and scrotum divided by thin wall into two cavities, each one of cavities occupied by the testis and epididymis (Fig. 1,2). These results agree with (Barone *et al.*, 2026; Kalita *et al.*, 2015). The testis of immature rabbit (45days) was curved elongated in shape and appear in dark brown in color. The testis of male rabbit at (45days) in ages was located inside the abdominal cavity that located in the lateral side of the cavity at each side and near the kidney. At this age according to the location. The scrotum was not clearly found. These results were agreement with (Nepal *et al.*, 2018) that observation is consistent which indicate that in many mammalian species, the testes initially develop intra-abdominally and descend into the scrotum during sexual maturation as part of normal developmental processes.

The morphological results show that the tests of rabbits at (150days) in age were elongated in the shape and appear pink in color, the tests at this age were differ from that in immature it was located outside of the body that was suspended with scrotum. Evidence provided by (Durairajanayagam *et al.*, 2015) who observed that change in position reflects the completion of testicular descent, which is essential for maintaining optimal temperature for spermatogenesis and confirms that the scrotal positioning is critical for cooling the testes and supporting efficient sperm production, as spermatogenesis is highly sensitive to temperature variations (Fig. 3,4).

Immature rabbit testis was present few different between two tests, in shape and color and at the morphological measurement, while the testis of mature rabbit, was largest differences between the right and left

testis in morphological measurement the appear the left testis was larger than the right (Fig. 5,6). These results support by (Barbosa *et al.*, 2024) mentioned that asymmetry where slight differences in testicular size are considered normal and may be related to variations in blood supply, vascular arrangement, or functional activity between the two sides.

Overall, these findings highlight the significant morphological changes that occur during sexual maturation in rabbits, particularly the transition from an intra-abdominal to a scrotal position, along with associated changes in color and size. These changes are closely linked to the functional development of the testes and the establishment of reproductive capacity.

The morphological results show the internal structure of the testis after making longitudinal section. That the testis consisted of capsule and driven trabeculae that divided it into lobule, the lobules was occupys with the seminiferous tubules with present of the rete testis and mediastinum. The tests of immature rabbit under the dissecting microscope appeared as semitransparent, where as in the mature rabbit appeared darker in color that was depending on differences in thickness of the testis between two ages (Fig. 5,6). These result support (Iczkowski *et al.*, 1991a). This study on prepubertal rabbit testes demonstrates a progressive increase in testicular volume and seminiferous tubule length with age. Although tubule diameter showed minimal change, the marked increase in tubular length and cellular content reflects the initiation and progression of spermatogenesis.

The weight of the left and right testis in immature rabbit (45days) and mature rabbit was measurement about (0.218±0.066g,0.142±0.016g), (1.196±0.036g, 0.939±0.063g) respectively, and there was statistically different between the two age (Table. 1,2,3,4). These results support with (Iczkowski *et al.*, 1991b). The increase in testicular width observed between immature and mature rabbits in the present study can be interpreted in light of morphometrical changes associated with testicular development. Similar observations were reported by (Chiarini-Garcia H, 2017).

Table 1: This table showing the weight of (right and left) tests of premature and mature rabbit (*Oryctolagus cuniculus*)

Age of animal	Weight of right tests mean±S.E (gm)	Weight of left tests mean±S.E (gm)
immature rabbit (45 days)	0.142±0.016*	0.218±0.066*
Mature rabbit (150 days)	0.939±0.063*	1.196±0.036*

Table 2: This table showing the length of right and left tests of premature and mature rabbit (*Oryctolagus cuniculus*)

Animal	Length Right tests mean±S.E (mm)	Length Left tests mean±S.E (mm)
immature rabbit (45 days)	9.74±0.43*	10.98±0.59*
Mature rabbit (150 days)	28.97±1.25*	30.72±1.66*

Table 3: This table showing the width of right and left testis of premature and mature rabbit (*Oryctolagus cuniculus*)

Age of animal	Width of right tests mean±S.E (mm)	Width of left tests mean±S.E (mm)
immature rabbit (45 days)	6.98±0.20*	7.44±0.210*
Mature rabbit (150 days)	23.58±1.26*	18.64±1.71*

Table 4: This table showing the thickness of right and left testis of premature and mature rabbit (*Oryctolagus cuniculus*)

Age of animal	Thickness of Right tests mean±S.E (mm)	Thickness of Left tests mean±S.E (mm)
immature rabbit (45 days)	4.36±0.52*	4.09±0.19*
Mature rabbit (150 days)	16.89±1.47*	15.37±1.02*

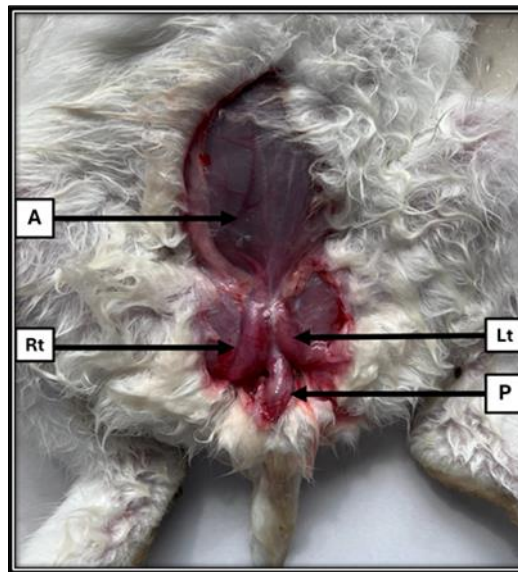


Figure 1: Photomicrograph ventral view after dissection perineal region of (45 days) immature in the male rabbit show: the testis at this age located inside the abdominal cavity: Right testis (Rt), Left testis (Lt), Abdominal wall(A) and Penis(P)

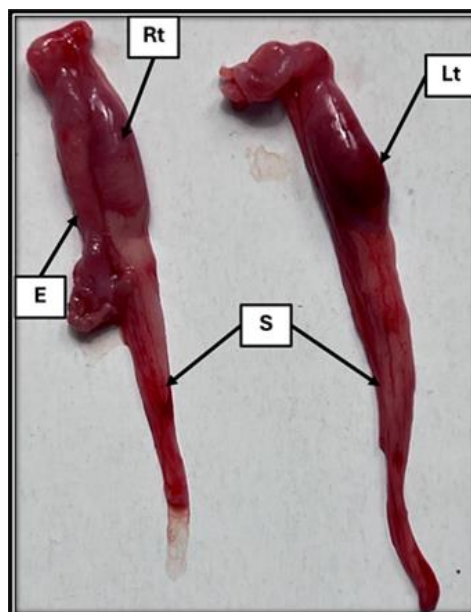


Figure 2: Photomicrograph of testes in age (45 days) immature in male rabbit show two testis outside body: Right testis (Rt), Left testis (Lt), Epididymis (E) and spermatic cord(S)

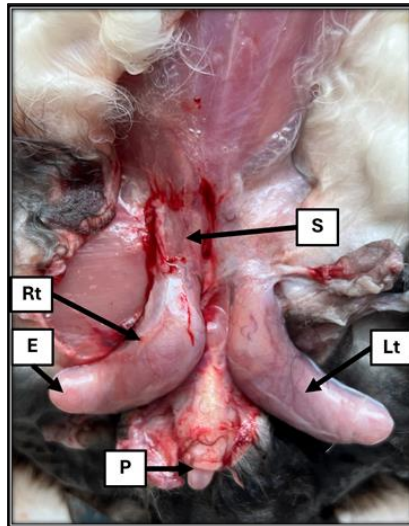


Figure 3: Photomicrograph of the testis in age (150 days) mature after after dissection of scrotum in male rabbit demonstrating their external shape and color show: Right testis (Rt), Left testis (Lt), Spermatic

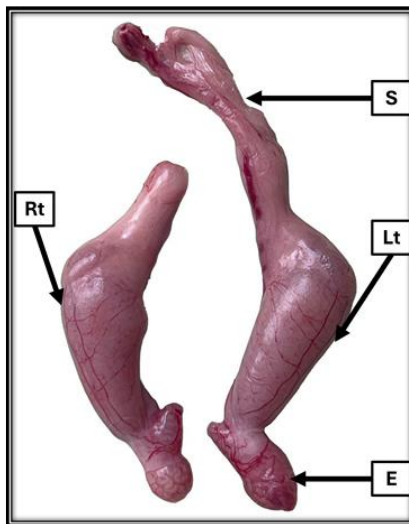


Figure 4: Photomicrograph of testes in age (150 days) mature of male rabbit show two testis outside body: Right testis (Rt), Left testis (Lt), Epididymis(E)and spermatic cord(S)

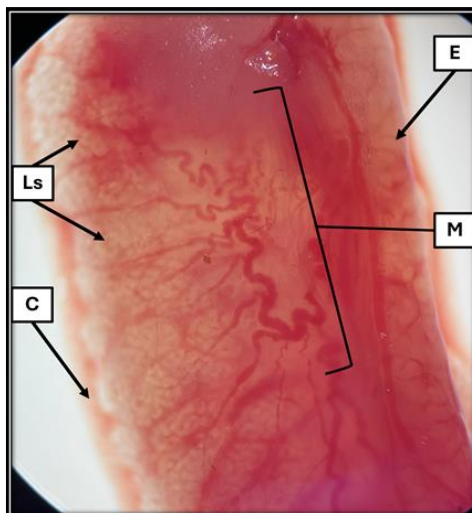


Figure 5: Photomicrograph longitudinal section of the testis in age (45 days) immature male rabbit examined under a dissecting(stereo) microscope show: Epididymis(E), Mediastinum(M), Lobe of seminiferous tubule

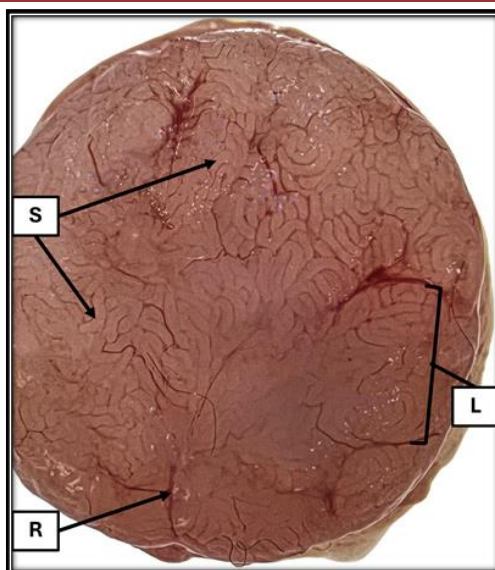


Figure 6: Photomicrograph cross section of the testis in age (150 days) mature male rabbit examined under a dissecting (stereo) microscope: Seminiferous tubule(S), Trabeculae(R)and lobe of seminiferous tubule

Acknowledgment

The authors express their sincere thankfulness for the support and facilities provided by Al-asim Green University/College of Veterinary Medicine.

Ethical Approval: The current research has followed the ethical conduct principles of the College of Veterinary Medicine accepted principles of ethical conduct by the college of veterinary medicine, University of Al-Qasim Green, qglc/qgec/98/2026.

Conflict of Interests: The authors declared they have no competing interests.

Funding: The study was funded by the authors only.

CRedit Author Statement

Hussam Khudhair Obais: Conceptualization, Methodology, Validation, Writing – Original Draft, Writing – Review and Editing.

Siraj Moner Al-kafagy: Conceptualization, Methodology, Review and Editing, Supervisor.

REFERENCES

- Hussein, A. A., & Abass, T. A. (2015). COMPARATIVE ANATOMICAL AND HISTOLOGICAL STUDY OF THE RABBITS (*Oryctolagus cuniculus*) ADRENAL GLAND AT THIRTY AND NINETY DAYS AGE. *Diyala Agricultural Sciences Journal*, 7(2). <https://www.cabdirect.org/cabdirect/abstract/20163140040>
- Lefèvre, B. M., Catté, D., Courtier-Orgogozo, V., & Lang, M. (2021). Male genital lobe morphology affects the chance to copulate in *Drosophila pachea*. *BMC Ecology and Evolution*, 21(1), 23. <https://doi.org/10.1186/s12862-021-01759-z>
- Caldeira, B. C., De Paula, T. a. R., Da Matta, S. L. P., Balarini, M. K., & Campos, P. K. A. (2010). Morphometry of testis and seminiferous tubules of the adult crab-eating fox (*Cerdocyon thous*, Linnaeus, 1766). *Revista CERES*, 57(5), 569–575. <https://doi.org/10.1590/s0034-737x2010000500001>
- Barone, B., Amicuzi, U., Tammara, S., Olivetta, M., Stizzo, M., Musone, M., Napolitano, L., De Luca, L., Reccia, P., Capone, F., Lecce, A., Pagano, G., Imperatore, S., Chianese, S., Papi, S., Della Rosa, G., Dinacci, F., Coppola, M., Madonna, A., . . . Crocetto, F. (2026). Male Infertility: A Comprehensive review of Urological Causes and contemporary management. *Journal of Clinical Medicine*, 15(1), 397. <https://doi.org/10.3390/jcm15010397>
- Kalita, A., Doley, P. J., Kalita, P., & Tolenkhomba, T. C. (2015). Morphology and Morphometry of Male Genital System of Zovawk: An Indigenous Pig of Mizoram. *Indian Journal of Veterinary Anatomy*, 27(1), 17–20. <http://citeseerx.ist.psu.edu/viewdoc/summary?doi=10.1.1.968.868>
- Nepal, P., Kumar, D., & Ojili, V. (2018). Abnormal descent of the testis and its complications: A multimodality imaging review. *South African Journal of Radiology*, 22(1), 1374. <https://doi.org/10.4102/sajr.v22i1.1374>
- Durairajanayagam, D., Agarwal, A., & Ong, C. (2014). Causes, effects and molecular mechanisms of testicular heat stress. *Reproductive BioMedicine Online*, 30(1), 14–27. <https://doi.org/10.1016/j.rbmo.2014.09.018>
- Barbosa, R. G., Favorito, L. A., & Sampaio, F. J. B. (2024b). Morphometric study applied to testicular and epididymis hydatids torsion. *Scientific Reports*, 14(1), 3249. <https://doi.org/10.1038/s41598-024-52734-9>

- Iczkowski, K. A., Sun, E. L., & Gondos, B. (1991). Morphometric study of the prepubertal rabbit testis: Germ cell numbers and seminiferous tubule dimensions. *American Journal of Anatomy*, 190(3), 266–272. <https://doi.org/10.1002/aja.1001900306>
- Chiarini-Garcia, H., Lima, M. Y. S., Reis, A. B., Martello, R., Nihi, F., Gomes, M. L. M., & Almeida, F. R. C. L. (2017b). Influence of three different histological methods on the morphology and morphometrical data in human testis. *PubMed*, 32(1), 27–34. <https://doi.org/10.14670/hh-11-765>.