

Original Research Article

Effects of Lutein on the Body Weights, Hepato-renal DNA and Antioxidant Capacity Following Paraquat-induced Toxicity in Wistar Rats

Edward Tolulope Adefola^{1*}, Ajibade Adeshina John², Edward Sylvester Sunday³

¹Department of Anatomy, Ladoke Akintola University of Technology (LAUTECH), Ogbomosho, Osun State, Nigeria

²Department of Anatomy, Ladoke Akintola University of Technology (LAUTECH), Ogbomosho, Osun State, Nigeria

³Department of Physiology, Obafemi Awolowo University (OAU), Ile-Ife, Osun State, Nigeria

*Corresponding Author: Edward Tolulope Adefola

Department of Anatomy, Ladoke Akintola University of Technology (LAUTECH), Ogbomosho, Osun State, Nigeria

Article History

Received: 16.09.2024

Accepted: 21.10.2024

Published: 25.10.2024

Abstract: *Introduction:* Paraquat is a leading cause of herbicide-related fatalities worldwide. Its high mortality rate is attributed to its inherent generation of ROS-mediated toxicity, and lack of effective treatment till date. Lutein is an antioxidant with free radical scavenging ability, which may contribute to its protective effects and possible DNA preservation. *Objective:* The study is evaluating the effects of lutein on body weights and hepato-renal antioxidant capacity with DNA quantification following paraquat toxicity in wistar rats. *Methods:* Thirty-five male Wistar rats (150-180g) rats were randomly divided into five equal groups (A-E). Paraquat toxicity was induced in Groups B-E with 5mg/kg for three days. Group A received normal saline only, while Group B was given paraquat only. Thereafter, Groups C-E received varying doses of lutein (50, 100, 150mg/kg) for 21 days. Their body weights were recorded twice weekly using a digital balance. The animals were sacrificed and their liver with kidneys were excised and processed. The photomicrographs were taken at various magnifications while Image J software was employed for DNA densities. The total antioxidant capacity (TAC) was assessed by Prieto method. *Results:* There was significant reductions in the body weights, ($p=0.00$) hepato-renal DNA densities ($p=0.00$, $p=0.01$) and antioxidant capacities of the PQ-only group relative to the positive control A in both liver and kidneys ($p=0.01$, $p=0.02$). However, the lutein-treated groups had dose-dependent similar features with the control, which had normal histo-morphological feature. The highest dose of lutein showed the best correlation with the control. *Conclusion:* This study showed significant alterations in body weights, hepato-renal DNA densities and antioxidant capacities especially in the PQ-only group. Meanwhile, the lutein-treated groups, especially at high dosages, showed significant improvements in the indices similar to the control. Hence, lutein may be a useful agent for attenuating paraquat toxicity.

Keywords: Paraquat, Lutein, DNA, Body weight, TAC.

INTRODUCTION

Paraquat (1, 1'-dimethyl-4,4'-dipyridylum) is a leading cause of herbicide-related fatalities worldwide, accounting for significant human mortality rates worldwide (Dawson *et al.*, 2010). In England and Wales, paraquat was responsible for 56% of pesticide-related deaths between 1945 and 1989 (Dargan *et al.*, 2006). The American Association of Poison Control Centers' National Poison Data System also reported paraquat as the leading cause of herbicide-related mortality in 2008 (Bronstein *et al.*, 2009).

Following accidental or deliberate ingestion of the toxic chemical, it is incompletely absorbed and rapidly distributed to lungs, liver, kidney, and muscle (Ujowundu *et al.*, 2018). The high incidence of its associated fatalities is attributed to its inherent toxicity and lack of effective treatment (Adejumo *et al.*, 2016). Paraquat's toxicity stems from its ability to undergo redox-cycling, and the generation of reactive oxygen species (ROS) (Yang *et al.*, 2007; Castello *et al.*, 2007). This mechanism causes mitochondrial damage in various cell lines, primarily through reduction by complex I (NADH ubiquinone oxidoreductase) in mitochondria (Cocheme and Murphy, 2008).

Copyright © 2024 The Author(s): This is an open-access article distributed under the terms of the Creative Commons Attribution 4.0 International License (CC BY-NC 4.0) which permits unrestricted use, distribution, and reproduction in any medium for non-commercial use provided the original author and source are credited.

Citation: Edward T. A, Ajibade A. J, Edward S. S (2024). Effects of Lutein on the Body Weights, Hepato-renal DNA and Antioxidant Capacity Following Paraquat-induced Toxicity in Wistar Rats. *South Asian Res J App Med Sci*, 6(5), 132-140. 132

Lutein, a potent antioxidant carotenoid, enhances kidney function and exhibits protective effects against ischemia-induced kidney damage (Gundogdu *et al.*, 2022, Gad El-Karim *et al.*, 2023). Studies have demonstrated lutein's potential to mitigate oxidative damage and degenerative conditions in the liver (Kim *et al.*, 2012). Its other pharmacological potentials include antioxidant, anti-inflammatory (Mammadov *et al.*, 2019), nephron-protective (Bilgic *et al.*, 2022), cardio-protective (Ouyang *et al.*, 2019), anti-neoplastic (Zhang *et al.*, 2018), and hepato-protective (Li *et al.*, 2015) activities. Lutein's free radical scavenging ability and promotion of antioxidant enzymes contribute to its protective and probably therapeutic effects (Hirdyani *et al.*, 2017). It decreases lipid peroxidation and attenuates the inflammatory responses (Kim *et al.*, 2012).

The lack of a proven antidote and standardized treatment guidelines for paraquat poisoning (Adejumo *et al.*, 2016) underscores the need for innovative preclinical therapeutic approaches. This study explores the potential of lutein, a potent antioxidant, to counteract paraquat-induced hepatic and renal DNA toxicity in Wistar rats, with the ultimate goal of reducing the burden of paraquat poisoning on human health.

MATERIALS AND METHODS

Experimental Design

Thirty-five male Wistar rats (150-180g) were used for the study after obtaining ethical approval. Following a two-week period of acclimatization, the rats were randomly divided into five equal groups (A-E) of seven per group.

Toxicity was induced in Groups B-E with 5mg/kg of paraquat for three days. Concurrently, Group A, which served as the positive control, received an equivalent volume of normal saline only, while Group B, the negative control, was given paraquat only. Twenty-four hours after the dosing, Groups C-E received varying doses of lutein (50, 100, 150mg/kg) once daily for 21 days. All the drugs were administered using oral cannula. The measurements of body weight were recorded twice weekly using a digital balance (Camry, China).

Tissue Collection, Histological and Biochemical Preparation:

Twenty-four hours after the final administration, the animals were euthanized, and their kidneys and liver were excised, fixed in 10% formol saline, and processed using paraffin wax embedding (Bancroft and Gamble, 2002). Feulgen staining of the sections was done in line with Bancroft and Gamble (2002). Examination was done using a motic Scanner; the photomicrographs were taken at various magnifications while Image J software was employed for DNA densities of the organs. Blood samples were collected via ocular puncture, centrifuged (2500rpm, 15min), and plasma stored at -20°C. The total antioxidant capacity (TAC) was done based on the reduction of Molybdenum-VI to Molybdenum-V and the subsequent formation of a green phosphate-molybdenum (V) complex at an acidic pH (Prieto *et al.*, 1999).

RESULTS

Percentage Body Weight Change

Figure 1 showed a significant reduction ($p=0.00$, $F=10.69$) in the percentage body weight in group B relative to the treated groups (C, D and E) which were given graded doses of lutein. There was also significant decrease ($p=0.00$) in the body weight of groups B, C and D when compared with the positive control (group A). Across the treated groups, there was a dose dependent significant increase ($p=0.00$) in the sequential weights when groups C, D and E were compared with one another.

Liver and Kidneys DNA Quantification

The control group in Plate 1 showed a uniformly arranged liver cells with high density of DNA within the nuclei. Similar finding is seen in the treated groups, which showed improvement in the density and arrangement of the nuclear element when compared with the control. In group B (PQ-only), the cellular elements were scanty with displacement in the alignment of the nuclear DNA. The hepatic DNA quantification in figure 2 showed a significant decrease ($p=0.00$, $F=109.72$) in group B, when compared with groups A, C, D and E. There was a significant increase in the treated groups (C-E) in a dose dependent fashion when compared with one another. Group A showed a significant increase ($p=0.00$) when compared with groups B, C, D, but had similar hepatic DNA count with group E which received the highest dose of lutein.

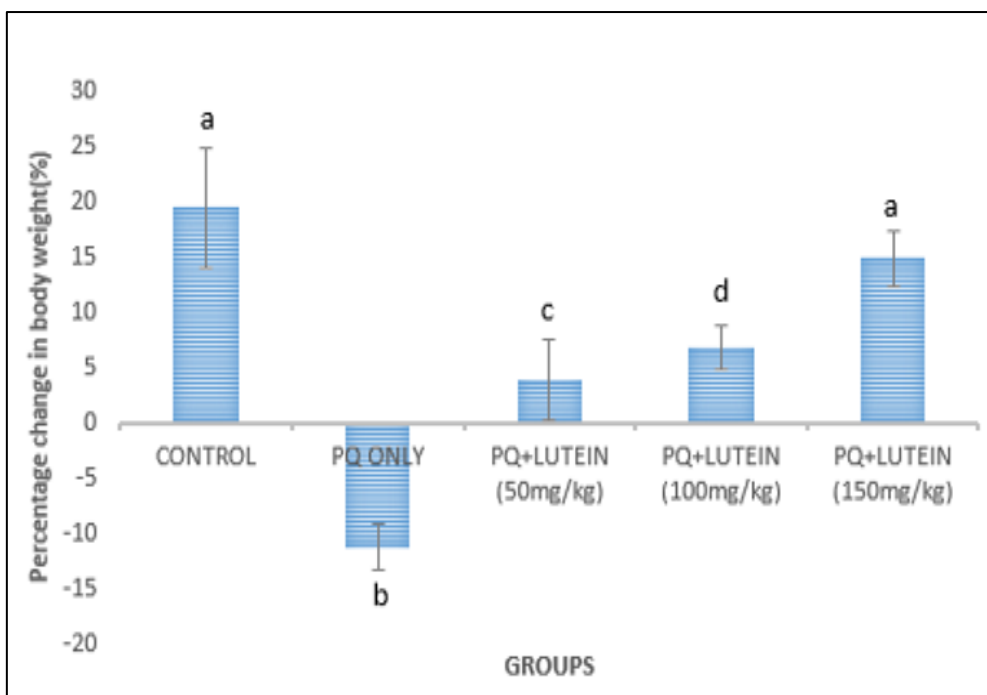


Figure 1: Shows percentage change in body weight: values are given Mean \pm SEM in each group. a, b, c, d within column signifies that mean with different letters differs significantly at $p= 0.05$, while mean with the same letter does not differ significantly at $p= 0.05$. PQ=Paraquat

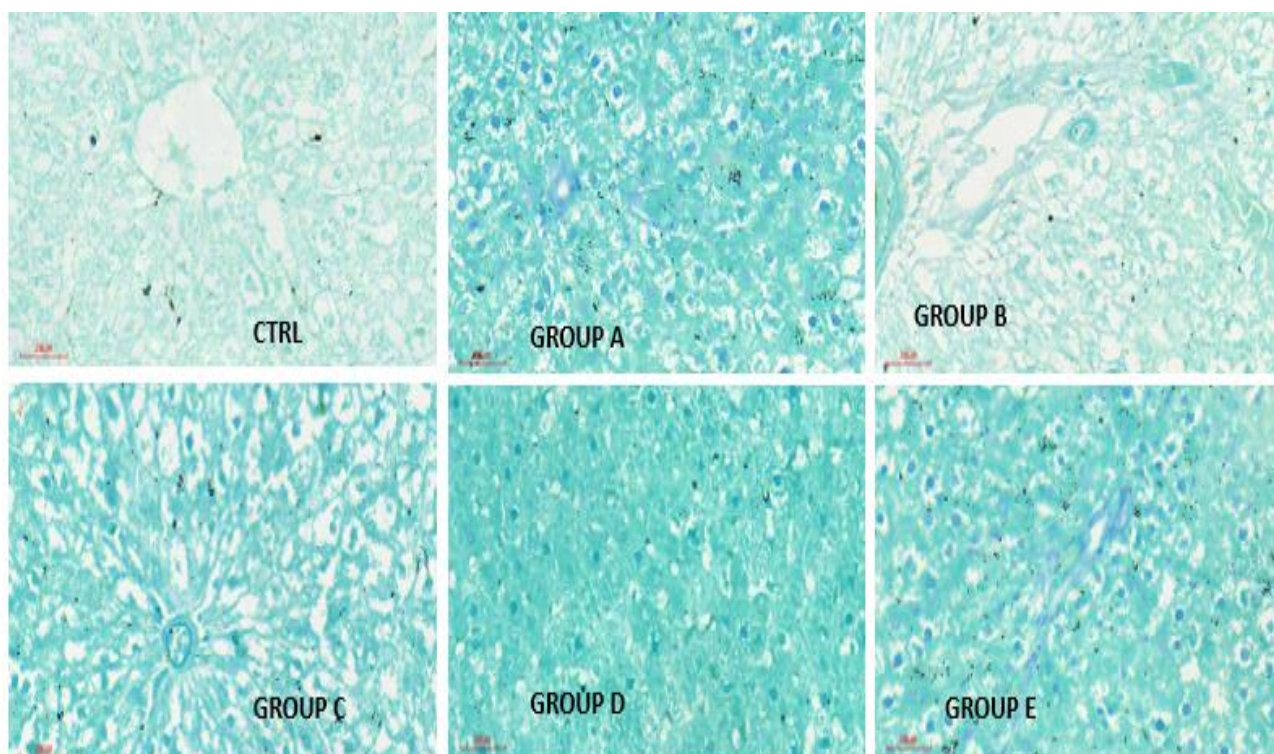


Plate 1: Photomicrographs of Liver Section Using Motic scanner: Group A (Control), B (Paraquat +Normal Saline), C (Paraquat+50mg/kg of Lutein), D (Paraquat+100mg/kg of lutein), E (Paraquat +150mg/kg of Lutein), CTRL-control for Feulgen. FeulgenX400

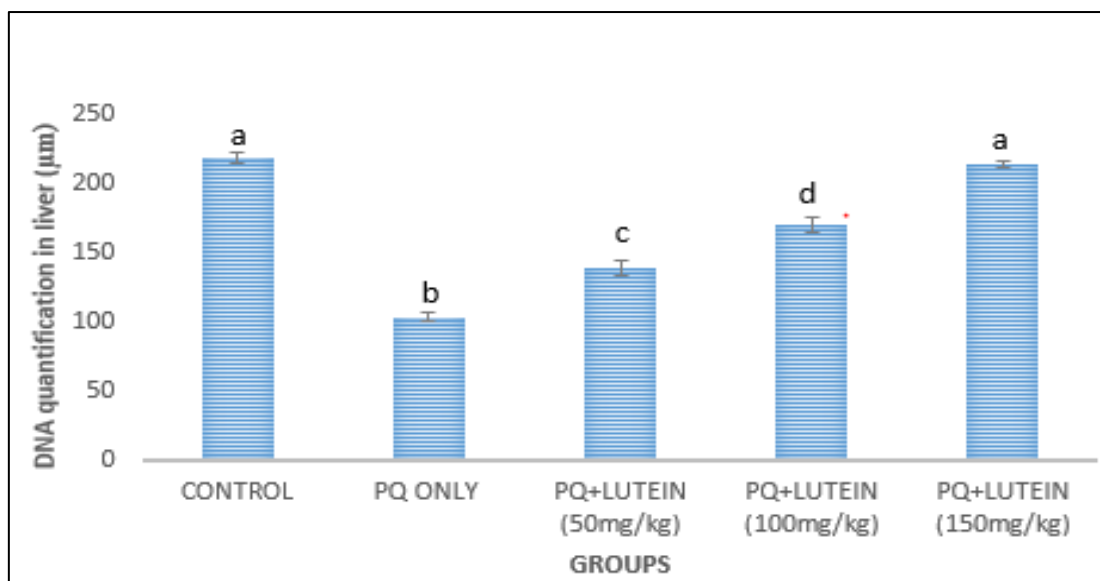


Figure 2: Shows DNA Quantification in the Liver Using Image J: values are given Mean ± SEM in each group. a, b, c and d within column signifies that mean with different letters differs significantly at p= 0.05 while mean with the same letter does not differ significantly at p= 0.05 PQ=Paraquat.

Plate 2 showed a high density of sequentially arranged DNA in the nuclei of group A. However, there were limited and disorganized nuclear DNA in group B, while the treated groups demonstrated an improved histological density of the nuclear element in a dose dependent version. Figure 3 showed insignificant difference in kidney DNA count between groups B (PQ only) and C (lowest dose of lutein), but the quantification was remarkably different when the two groups were compared with the control, and groups D and E (p= 0.01, F=24.65), which had higher doses of lutein. Although the control showed a significant increase (p=0.01) when compared with groups B, C, D, there was no significant difference in kidney DNA count when it (group A) was compared with group E which had the highest dose of lutein.

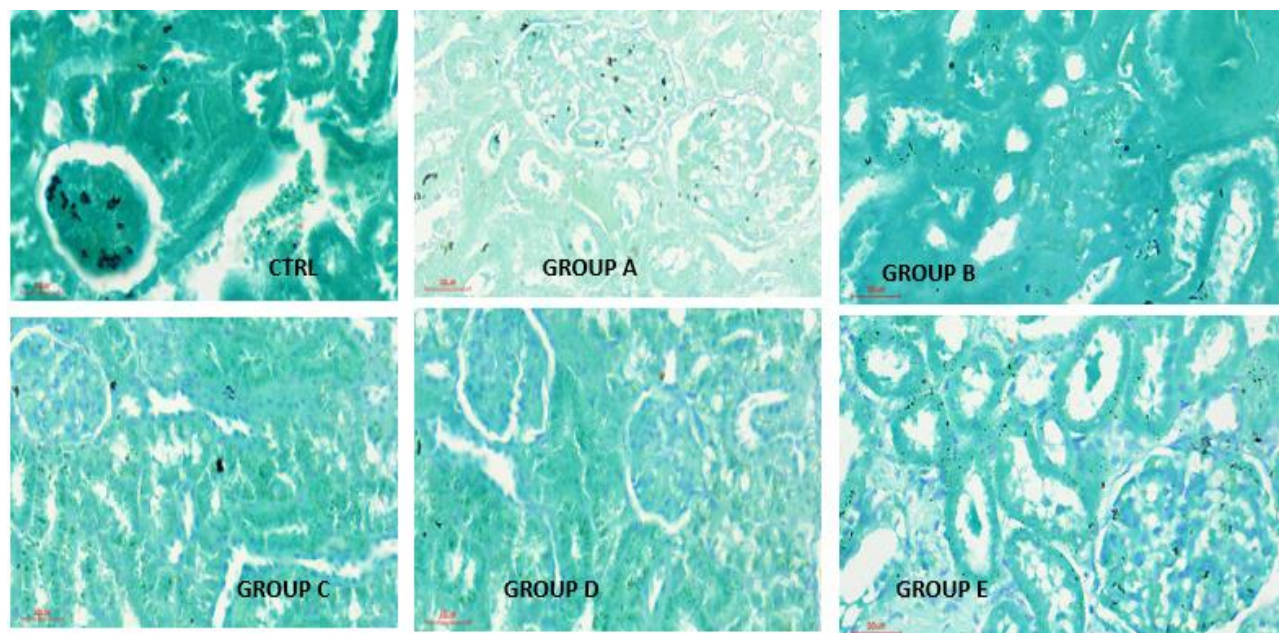


Plate 2: Photomicrograph of Kidney Tissue using Motic scanner: A (Control), B (Paraquat+Normal saline), C (Paraquat+50mg/kg of Lutein), D (Paraquat+100mg/kg of Lutein), E (Paraquat+150mg/kg), F (40mg/kg of Vitamin C), G (Paraquat+ 40mg/kg of Vitamin C). CTRL-control for Feulgen. Feulgen (X400).

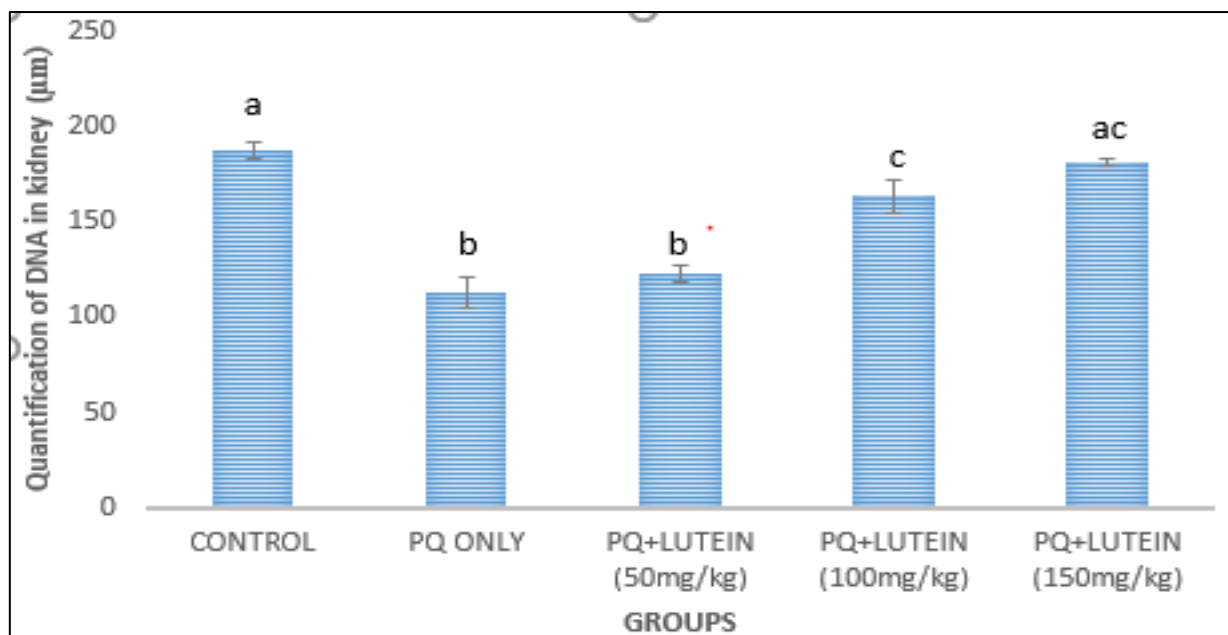


Figure 3: Shows DNA Quantification in the Kidney Using Image J: values are given Mean ± SEM in each group. a, b, c, within column signifies that mean with different letters differs significantly at $p= 0.05$ while mean with the same letter does not differ significantly at $p= 0.05$. PQ=Paraquat and VIT.C= Vitamin C.

Total Antioxidant Capacity of the Liver and Kidney

The liver and kidney total antioxidant capacities were lowest in group B, but highest in the control and group E (Figures 4 and 5). Hence, group B was significantly lower compared with groups D and E for both liver and kidney ($p= 0.01$ and $p=0.02$). For both organs, there was no significant difference between groups B and C; similarly, there was no remarkable difference between the control, groups D and E.

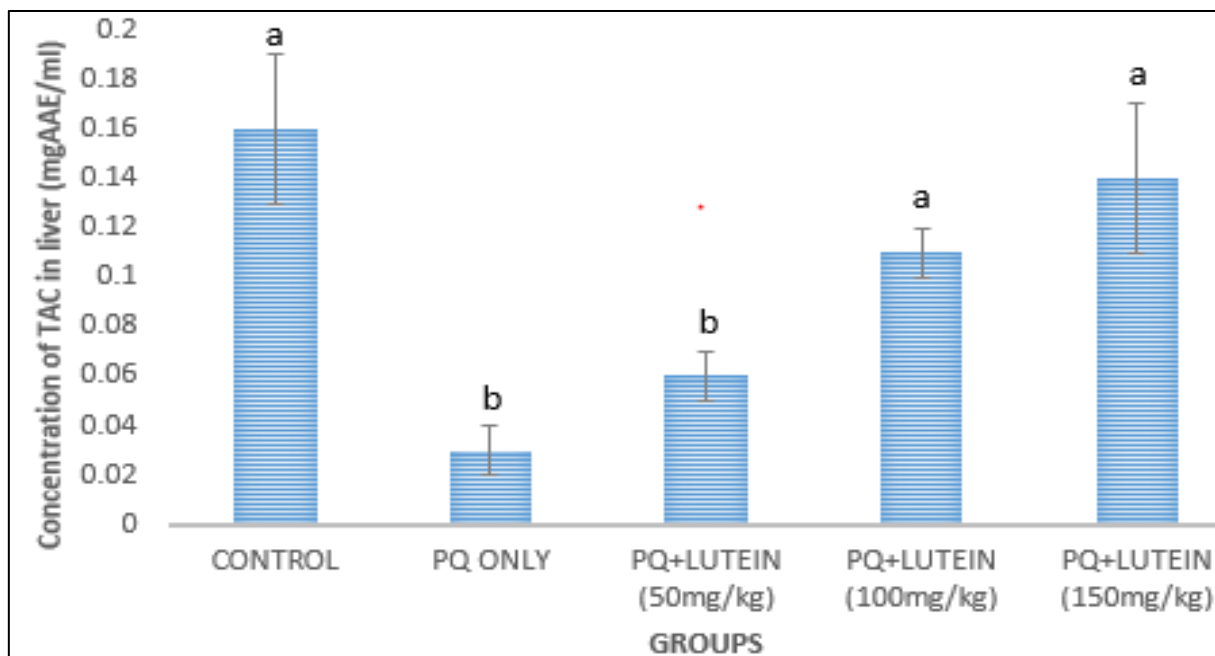


Figure 4: Shows Concentration of Total Antioxidant Capacity (TAC) in the liver: values are given Mean ± SEM in each group. a, b, within column signifies that mean with different letters differs significantly at $p= 0.05$ while mean with the same letter does not differ significantly at $p= 0.05$. PQ=Paraquat.

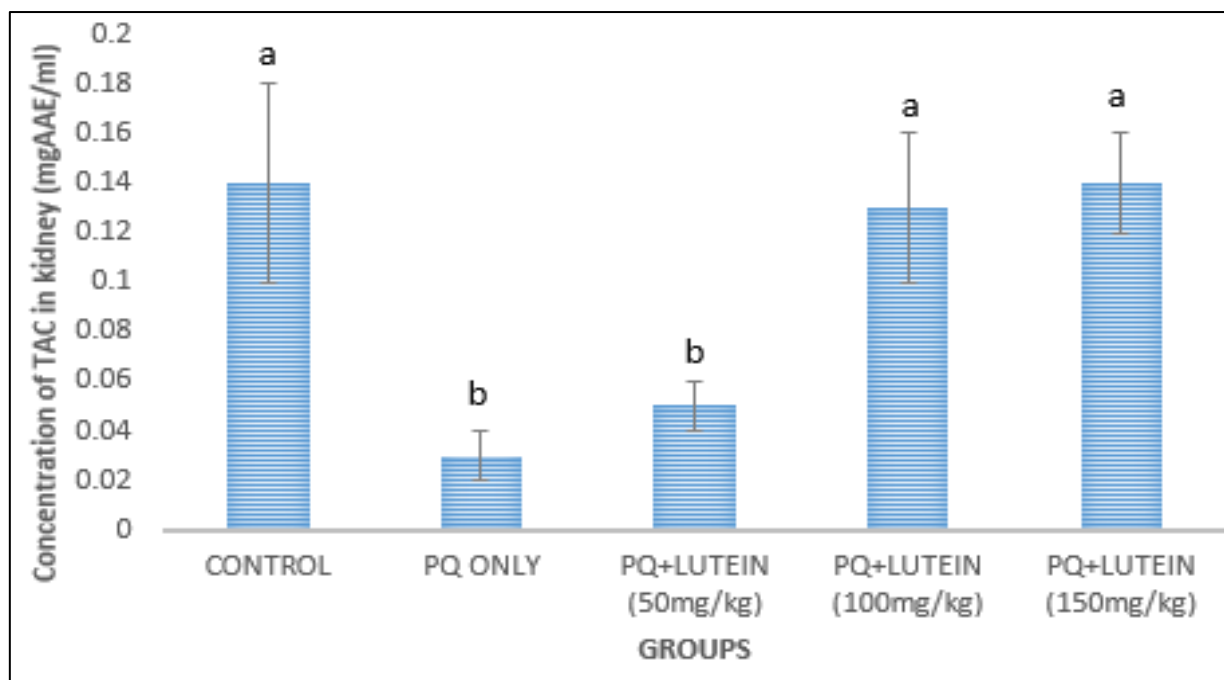


Figure 5: Shows Concentration of Total Antioxidant Capacity (TAC) in the kidney: values are given Mean \pm SEM in each group. a, b, within column signifies that mean with different letters differs significantly at $p= 0.05$ while mean with the same letter does not differ significantly at $p= 0.05$. PQ=Paraquat.

DISCUSSION

The study showed a significant decrease in the percentage body weight of the rats treated with paraquat only when compared with the control and the treated groups. This is similar to the findings by Edo *et al.*, (2022) reported significant weight loss in Wistar rats exposed to PQ for 14 days; this was attributed to reduced food intake and increased oxidative stress as also observed by Goudarzi *et al.*, (2014). Ofusori *et al.*, (2008) also reported that paraquat-induced generation of free radicals and their systemic cytokines may be linked to weight loss in wistar rats. In line with studies by Pourgholamhossein *et al.*, (2018) and Reddy *et al.*, (2019), gastrointestinal tract toxicity as a result of oxidative damage and subsequent mucosa ulceration may alter feeding pattern leading to weight reduction. Similarly, Mohamed *et al.*, (2015) and Hassan *et al.*, (2018) found about 25 % decrease in body weight of Wistar rats treated with PQ for three weeks.

As shown in the results, the steady and significant increase in the weight of the lutein-treated groups when compared with the PQ-only group, may be due to the anti-inflammatory and anti-oxidant potential of the chemical (Zhao *et al.*, 2023; Li *et al.*, 2015), leading to repair of the gastrointestinal tract.

The present study also showed a significant decrease in DNA density of the kidney and liver tissue in group B relative to others. This is indicative of cellular degeneration, which is akin to the findings by Onur *et al.*, (2022); the authors reported that genotoxic effects can result from the interaction of DNA and its related proteins with paraquat causing protein-associated DNA breaks. Related finding was reported by Soheila *et al.*, (2022) who worked on paraquat induced oxidative stress, DNA damage and cytotoxicity in lymphocytes. In line with other studies, PQ-induced oxidative stress causes DNA damage and fragmentation in Wistar rats as observed by Mohamed *et al.*, 2015 and Bhattacharya *et al.*, 2020. Similarly, Li *et al.*, (2018) and Serpeloni *et al.*, (2019) reported increased DNA damage in liver and kidney tissues of Wistar rats treated with PQ for one week.

As observed in the lutein-treated groups, the DNA density significantly increase in a dose dependent manner as shown in the photomicrographs. The anti-inflammatory hepatoprotective effect may be attributed to this finding (Li *et al.*, 2015). Feulgen, a histochemical stain specific for DNA, is frequently damaged in cells exposed to reactive oxygen species (Demirbag *et al.*, 2005). DNA damage may be evident by changes in structure, its encoding properties or cell cycle interference.

There was a significant reduction in the total antioxidant capacities (TAC) of the paraquat only group which is similar to findings (Jiaxin *et al.*, 2022; Atashpour *et al.*, 2017). This confirmed the role of free radical generation and attenuation of antioxidant level in paraquat mediated renal and hepatic injury through oxidative damage. Similar to other reports, PQ poisoning decreases TAC in liver and kidney tissues, indicating impaired antioxidant defenses (Li *et al.*, 2018;

Serpeloni *et al.*, 2019). A study by Hassan *et al.*, (2018) and Bhattacharya *et al.*, (2020) found significant a 35-45% reductions in liver TAC, and a 25-35% decline in kidney TAC in Wistar rats exposed to PQ for 14 days.

However, there was significant increase of TAC in the groups treated with graded dosage of lutein in a dose dependent fashion, this may be linked to the antioxidant property of lutein (Fuad *et al.*, 2020; Li *et al.*, 2015), which has been known to counteract hydroxyl (HO•), peroxy (ROO•), superoxide anion (O₂•-) and hypochlorous acid (HOCl) than other carotene and lycopene. Total antioxidant capacity is an indicator of blood, cells and tissues defense system against free radicals and all antioxidants present in a biological sample (Ferrari 2012).

Findings have shown that weight loss correlates with decreased TAC and increased DNA damage in PQ-treated Wistar rats as reported by Edo *et al.*, (2022). Studies by Hassan *et al.*, (2018) and Serpeloni *et al.*, 2019) found that reduced TAC and increased DNA damage contributed to PQ-induced hepatorenal toxicity and weight loss. However, antioxidant supplementation with lutein may mitigate PQ-induced oxidative stress and weight loss (Serpeloni *et al.*, 2019). Anti-inflammatory compounds may reduce PQ-induced inflammation and DNA damage (Li *et al.*, 2018).

CONCLUSION

This study showed significant alterations in body weights, hepato-renal DNA densities and antioxidant capacities especially in the PQ-only group. Meanwhile, the lutein-treated groups, especially at high dosages, showed significant improvements in the indices similar to the control. Hence, lutein may be a useful agent for attenuating paraquat toxicity.

Source(s) of Support: Nil

Presentation at a Meeting: Nil

Conflicting Interest: Nil

Acknowledgement: Nil

REFERENCES

- Adejumo, O. A., Akinbodewa, A. A., Olafisoye, O. J., & Afolabi, O. N. (2016). Acute kidney injury following paraquat poisoning: An uncommon case of acute toxic nephropathy in Nigeria. *Journal of Medicine in the Tropics*, 18(1), 51-53.
- Ahmed, M. M. (2010). Radio and chemo protective properties of hesperidin against genotoxicity induced by gamma radiation and/or paraquat in rat bone marrow cells. *Egyptian Journal of Radiation Sciences and Applications*, 23.
- Atashpour, S., Kargar Jahromi, H., Kargar Jahromi, Z., & Zarei, S. (2017). Antioxidant effects of aqueous extract of Salep on Paraquat-induced rat liver injury. *World J Hepatol*, 9(4), 209-216.
- Bhattacharya, S., et al. (2020). Paraquat-induced DNA damage and apoptosis in rat liver cells. *Environmental Toxicology*, 35(5), 537-546.
- Bilgiç, S., Gür, F. M., & Aktaş, İ. (2022) Biochemical and Histopathological Investigation of the Protective Effect of Lutein in Rat Kidney Exposed to Cisplatin. *Med. Rec*, 4, 433–438.
- Bronstein, A. C., Spyker, D. A., Cantilena JR, MD, PhD, L. R., Green, J. L., Rumack, B. H., & Giffin, S. L. (2009). Annual report of the American Association of Poison Control Centers' national poison data system (NPDS): 27th annual report. *Clinical Toxicology*, 48(10), 979-1178.
- Castello, P. R., Drechsel, D. A., & Patel, M. (2007). Mitochondria are a major source of paraquat-induced reactive oxygen species production in the brain. *Journal of biological chemistry*, 282(19), 14186-14193.
- Cochemé, H. M., & Murphy, M. P. (2008). Complex I is the major site of mitochondrial superoxide production by paraquat. *Journal of biological chemistry*, 283(4), 1786-1798.
- Dargan, P., Shiew, C. M., Greene, S. L., Gawarammana, I. B., & Jones, A. L. (2006, January). Paraquat poisoning: Caution in interpreting prognosis based on plasma paraquat concentrations. In *Clinical Toxicology* (Vol. 44, No. 5, pp. 762-763).
- Dawson, A. H., Eddleston, M., Senarathna, L., Mohamed, F., Gawarammana, I., Bowe, S. J., ... & Buckley, N. A. (2010). Acute human lethal toxicity of agricultural pesticides: a prospective cohort study. *PLoS medicine*, 7(10), e1000357.
- Demmig-Adams, B., López-Pozo, M., Stewart, J. J., & Adams III, W. W. (2020). Zeaxanthin and lutein: Photoprotectors, anti-inflammatories, and brain food. *Molecules*, 25(16), 3607.e0119288.
- Edo, G. I. (2022). Effects of paraquat dichloride on adult male wistar rat. an approach in the toxicity of body weights and hematological tissues. *J Anal Pharm Res*, 11(1), 1-7
- Ferrari, C. K. Effects of xenobiotics on total antioxidant capacity. *Interdiscip Toxicol*, 5(3), 117–122.

- Fuad, N. I. N., Sekar, M., Gan, S. H., Lum, P. T., Vaijanathappa, J., & Ravi, S. L. (2020). A Comprehensive Review on its Chemical, Biological Activities and Therapeutic Potentials. *Pharmacogn J*, 12(6)Suppl, 1769-78
- Gad El-Karim, D. R., Lebda, M. A., Alotaibi, B. S., El-Kott, A. F., Ghamry, H. I., & Shukry, M. (2023). Lutein Modulates Oxidative Stress, Inflammatory and Apoptotic Biomarkers Related to Di-(2-Ethylhexyl) Phthalate (DEHP) Hepato-Nephrotoxicity in Male Rats: Role of Nuclear Factor Kappa B. *Toxics*, 11(9), 742.
- Goudarzi, F., Armandeh, J., Jamali, K., Rahmati, H., Meisami, A., & Abbasi, H. (2014). Mortality analysis of patients with paraquat poisoning treated at two university hospitals in Shiraz, Iran. *Journal of Toxicology and Clinical Toxicology*, 52(3), 258-264.
- Gündoğdu, B., Taş, H. A. K. A. N., Süleyman, B., Mamedov, R., Yüce, N., Kuyrukluıldiz, U., & Süleyman, H. (2022). Effect of lutein on oxidants and proinflammatory cytokine-related liver ischemia-reperfusion injury. *Acta Poloniae Pharmaceutica-Drug Research*, 79(1).
- Hassan, M. A., et al. (2018). Paraquat-induced oxidative stress and hepatorenal damage in rats. *Journal of Toxicology and Environmental Health, Part B*, 21(5), 347-359.
- Hirdyani, H., & Sheth, M. (2017). Lutein—The less explored carotenoid. *World J. Pharm. Res*, 6, 528-553.
- Jiabin, C., Yalin, S., Fei, L., Mujahid, I., Khalid, M., Hui, Z., & Dayou, S. (2021). Effect of paraquat on cytotoxicity involved in oxidative stress and inflammatory reaction: A review of mechanisms and ecological implications. *Ecotoxicology and Environmental Safety*, 224, 112711. ISSN 0147-6513. <https://doi.org/10.1016/j.ecoenv.2021.112711>.
- Kim, J. E., Clark, R. M., Park, Y., Lee, J., & Fernandez, M. L. (2012). Lutein decreases oxidative stress and inflammation in liver and eyes of guinea pigs fed a hypercholesterolemic diet. *Nutrition research and practice*, 6(2), 113-119.
- Li, H., Deng, Z., Liu, R., Loewen, S., & Tsao, R. (2013). Carotenoid compositions of coloured tomato cultivars and contribution to antioxidant activities and protection against H₂O₂-induced cell death in H9c2. *Food Chemistry*, 136(2), 878-888.
- Li, S., Ding, Y., Niu, Q., Xu, S., Pang, L., Ma, R., ... & Guo, S. (2015). Lutein has a protective effect on hepatotoxicity induced by arsenic via Nrf2 signaling. *BioMed Research International*, 2015(1), 315205.
- Mammadov, R., Suleyman, B., Akturan, S., Cimen, F. K., Kurt, N., Suleyman, Z., & Malkoc, İ. (2019). Effect of lutein on methotrexate-induced oxidative lung damage in rats: a biochemical and histopathological assessment. *The Korean journal of internal medicine*, 34(6), 1279–1286.
- Mohamed, F., Endre, Z., Jayamanne, S., Pianta, T., Peake, P., Palangasinghe, C., ... & Buckley, N. (2015). Mechanisms underlying early rapid increases in creatinine in paraquat poisoning. *PLoS One*, 10(3), e0122357.
- Ofusori, D. A., Caxton-Martins, E. A., S. T., Oluwayinka, P. O., Abayomi, T. A., & Ajayi, S. A. (2008). Microarchitectural adaptation s in the stomach of African trese Pangolin (*Manis tricuspis*). *International Journal of morphology*, 26(3), 701-5.
- Onur, B., Çavuşoğlu, K., Yalçın, E., & Acar, A. (2022). Paraquat toxicity in different cell types of Swiss albino mice. *Scientific reports*, 12(1), 4818. <https://doi.org/10.1038/s41598-022-08961->
- Ouyang, B., Li, Z., Ji, X., Huang, J., Zhang, H., & Jiang, C. (2019). The protective role of lutein on isoproterenol-induced cardiac failure rat model through improving cardiac morphology, antioxidant status via positively regulating Nrf2/HO-1 signalling pathway. *Pharmaceutical biology*, 57(1), 529-535.
- Pourgholamhossein, F., Rasooli, R., Pournamdari, M., Pourgholi, L., Samareh-Fekri, M., Ghazi-Khansari, M., ... & Mandegary, A. (2018). Pirfenidone protects against paraquat-induced lung injury and fibrosis in mice by modulation of inflammation, oxidative stress, and gene expression. *Food and chemical toxicology*, 112, 39-46.
- Reddy, K. B. A. K., Jeevanalatha, M., Lakshman, M., & Rani, M. U. (2019). The toxic effects of paraquat (PQ) on body weights and haematological parameters in male albino wistar rats and its amelioration with vitamin C. *Int. J. Curr. Microbiol. App. Sci*, 8(11), 314-320.
- Serpeloni, J. M., de Syllos Colus, I. M., de Oliveira, F. S., Aissa, A. F., Mercadante, A. Z., Bianchi, M. L. P., & Antunes, L. M. G. (2014). Diet carotenoid lutein modulates the expression of genes related to oxygen transporters and decreases DNA damage and oxidative stress in mice. *Food and chemical toxicology*, 70, 205-213.
- Sindhu, E. R., Preethi, K. C., & Kuttan, R. (2010). Antioxidant activity of carotenoid lutein in vitro and in vivo. *Indian J Exp Biol*, 48, 843-8.
- Ujowundu, C. O., Nwaogu, L. A., Ujowundu, F. N., Oparaeché, N. N., & Oyarebu, A. O. (2018). Hepatotoxicity of paraquat dichloride and ameliorative effect of nutritional supplements. *Biochem. Mol. Biol. J*, 4, 21.
- Wang, M., Tsao, R., Zhang, S., Dong, Z., Yang, R., Gong, J., & Pei, Y. (2006). Antioxidant activity, mutagenicity/anti-mutagenicity, and clastogenicity/anti-clastogenicity of lutein from marigold flowers. *Food and chemical toxicology*, 44(9), 1522-1529.
- Yamada, K., & Fukushima, T. (1993). Mechanism of cytotoxicity of paraquat: II. Organ specificity of paraquat-stimulated lipid peroxidation in the inner membrane of mitochondria. *Experimental and Toxicologic Pathology*, 45(5-6), 375-380.
- Yang, W., & Tiffany-Castiglioni, E. (2007). The bipyridyl herbicide paraquat induces proteasome dysfunction in human neuroblastoma SH-SY5Y cells. *Journal of Toxicology and Environmental Health, Part A*, 70(21), 1849-1857.

- Zhang, W. L., Zhao, Y. N., Shi, Z. Z., Cong, D., & Bai, Y. S. (2018). Lutein Inhibits Cell Growth and Activates Apoptosis via the PI3K/AKT/mTOR Signaling Pathway in A549 Human Non-Small-Cell Lung Cancer Cells. *Journal of environmental pathology, toxicology and oncology: official organ of the International Society for Environmental Toxicology and Cancer*, 37(4), 341–350.
- Zhao, S., Zhang, Y., Ding, H., Hu, S., Wu, X., Ma, A., & Ma, Y. (2023). Lutein Prevents Liver Injury and Intestinal Barrier Dysfunction in Rats Subjected to Chronic Alcohol Intake. *Nutrients*, 15(5), 1229.